

Congenital ptosis repair—surgical, cosmetic, and functional outcome: a report of 162 cases

Alon Skaat, MD, Didi Fabian, MD, Abraham Spierer, MD, Nachum Rosen, MD, Mordechai Rosner, MD, Guy J. Ben Simon, MD

ABSTRACT • RÉSUMÉ

Objective: To evaluate the surgical and functional outcome of congenital ptosis repair and the anisometropic changes after surgical repair of ptosis to determine the potential contribution of anisometropia to the development of refractive amblyopia.

Methods: The clinical records of 162 children with congenital ptosis that had been surgically repaired between 1995 and 2006 at the Goldschleger Eye Institute were reviewed and analyzed for functional and cosmetic outcome, visual acuity status, and presence of amblyopia.

Results: A total of 162 patients (mean age, 10 months) underwent surgical ptosis repair, of whom 120 (74%) had unilateral and 42 (26%) had bilateral ptosis. The surgeries were levator resection (47.5%), frontalis suspension (46.3%), and Fasanella-Servat (7.4%). Good functional and cosmetic outcomes were achieved in 130 (80.2%) patients, with unilateral cases showing more postoperative asymmetry. The reoperation rate was 10.4% (8/77) for levator resection, 29.3% (22/75) for frontalis suspension, and 20% (2/10) for Fasanella-Servat. There were no significant differences in visual acuity, spherical equivalent, or mean cylinder at 90° between the ptotic eyes before and after surgery ($P = 0.33$, $P = 0.83$, and $P = 0.65$, respectively), and compared with the sound eyes ($P = 0.66$, $P = 0.78$, and $P = 0.08$, respectively). The mean astigmatism correction by vector analysis after ptosis surgery was 1.1 ± 0.68 D.

Conclusions: Congenital ptosis repair yields good functional and cosmetic outcome, although the reoperation rate is relatively high (19.8%). Congenital unilateral ptosis was not associated with any differences in anisometropia or astigmatism between the ptotic and sound eye.

Objet : Évaluation des résultats chirurgicaux et fonctionnels du relèvement de la ptose congénitale et des modifications anisométriques après le relèvement chirurgical de la ptose, afin de déterminer les possibilités de contribution de l'anisométrie au développement de l'amblyopie réfractive.

Méthodes : Révision et analyse des dossiers cliniques de 162 enfants atteints de ptose congénitale relevée chirurgicalement entre 1995 et 2006 au Goldschleger Eye Institute, quant aux résultats fonctionnels et cosmétiques, au degré d'acuité visuelle et à la présence de l'amblyopie.

Résultats : En tout, 162 patients (âgés de 10 mois en moyenne) ont subi une chirurgie réparatrice de la ptose. Parmi eux, 120 (74 %) avaient une ptose unilatérale et 42 (26 %), une ptose bilatérale. Les chirurgies furent la résection des élévateurs (47,5 %), la suspension frontale (46,3 %) et la Fasanella-Servat (7,4 %). De bons résultats fonctionnels et cosmétiques ont été atteints chez 130 patients (80,2 %), avec des cas unilatéraux montrant plus d'asymétrie postopératoire. Les taux de réopération étaient de 10,4 % (8/77) des résections des élévateurs, 29,3 % (22/75) des suspensions frontales et 20 % (2/10) des Fasanella-Servat. Il n'y avait pas de différence significative d'acuité visuelle, d'équivalence sphérique ou de moyenne cylindrique de 90° entre les yeux ptotiques avant et après la chirurgie ($P=0,33$, $P=0,83$ et $P=0,65$ respectivement), et à comparer aux yeux sains ($P= 0,66$, $P=0,78$, et $P=0,08$, respectivement). La moyenne de correction de l'astigmatisme par analyse vectorielle après la chirurgie de la ptose était de $1,1 \pm 0,68$ dioptries.

Conclusion : La réparation de la ptose congénitale donne de bons résultats fonctionnels et cosmétiques, bien que le taux de réopération soit relativement élevé (19,8 %). La ptose congénitale unilatérale n'était pas associée avec toute différence d'anisométrie ou d'astigmatisme entre l'œil ptotique et l'œil sain.

Congenital ptosis is present at birth and is usually recognized by the parents or pediatrician during the first weeks of life. Its most common cause is levator muscle dysgenesis that usually presents unilaterally. A complete preoperative evaluation is essential for ensuring proper diagnosis and selecting the correct procedure. Congenital ptosis may be associated with visual disturbances in addition to being a cosmetic problem, and early correction is usually indicated to prevent amblyopia (lazy eye).¹⁻³ Amblyopia may be the result of visual axis

obscuration by the droopy eyelid (stimulus deprivation) or induced by corneal changes and astigmatism (refractive or astigmatic, respectively).^{1,2} Amblyopia may be more common in cases of unilateral or asymmetric ptosis because of normal visual pathway development on one side and pathologic development on the other side. It is therefore imperative to examine all children with congenital ptosis for the presence of amblyopia and to surgically treat the ones who have it as soon as possible.^{4,5}

From the Goldschleger Eye Institute, Sheba Medical Center, Tel Hashomer, affiliated to the Sacker Faculty of Medicine, Tel Aviv University, Tel Aviv, Israel

Originally received Jun. 2, 2012. Final revision Aug. 25, 2012. Accepted Sep. 25, 2012

Correspondence to Skaat Alon, MD, Goldschleger Eye Institute, Sheba Medical Center, Tel Hashomer, Israel 52621; skaatalon@gmail.com

Can J Ophthalmol 2013;48:93-98

0008-4182/13/\$-see front matter © 2013 Canadian Ophthalmological Society. Published by Elsevier Inc. All rights reserved.
<http://dx.doi.org/10.1016/j.jjo.2012.09.010>

The correlation between congenital ptosis and amblyopia continues to be a source of controversy. Several studies have shown that congenital ptosis and the development of amblyopia are correlated, and that the depth of amblyopia may be proportional to the severity of the ptosis.¹⁻⁵ There are, however, some data to support the idea that amblyopia is a matter of pure deprivation, in which case, surgical correction of the ptosis should aid in improving the visual outcome.⁵ If, in contrast, there is a major refractive component,⁶⁻⁸ surgery may either increase or contribute to the anisometropic and astigmatic changes that can provoke the development of amblyopia in these patients.³ Moreover, a ptotic eyelid might induce astigmatic changes during embryonic development that can stimulate anisometropic or astigmatic amblyopia at a later stage; this is in addition to stimulus deprivation with partial or complete obliteration of the visual axis.^{1,2} These issues become significant when there is a question of if and when congenital ptosis should be treated surgically. The purpose of this study was to evaluate functional and cosmetic outcomes of various surgical techniques for treating congenital ptosis, and to investigate the relationship between ptosis and the development of amblyopia.

METHODS

The medical records of all patients with congenital ptosis that had been surgically corrected at the Goldschleger Eye Institute, Sheba Medical Center between January 1995 and November 2006 were reviewed. Patients with acquired ptosis, a history of any previous surgery (intraocular, strabismus, or lid), synkinetic movements of the upper lid, and corneal abnormalities were excluded. Clinical information was supplemented by patient and parent recall, as well as follow-up records obtained from referring physicians.

The preoperative and postoperative assessment included functional and cosmetic outcome, eyelid asymmetry (defined as <1 mm difference between both eyelids), uncorrected visual acuity (VA), and best corrected VA (BCVA) measured by age-appropriate methods, and complete ophthalmic and orthoptic examinations. The retrieved data on astigmatism included measurements of the spherical equivalent (SE), the positive cylinder power, and the orientation of the steeper meridian (in degrees), and they were reviewed and used for statistical analysis. Difference in refraction in both eyes (anisometropia) was defined as a greater than 1.00 D difference between the eyes in SE, or a difference between the eyes in astigmatism in any meridian on cycloplegic refraction that was more than 1.00 D.³

Amblyopia was defined as BCVA less than 20/40 and greater than 2 Snellen lines of difference between the 2 eyes. Amblyopia in younger patients was defined by a

lack of fixation by the induced tropia test in the ptotic eye compared with the nonptotic eye.

The ocular alignment and ocular motility were assessed in all cases. The ptosis was evaluated by measuring the severity of the ptosis, the upper lid excursion for assessment of the levator palpebrae action, and examination of the upper lid crease. Surgical correction was performed by two surgeons (N.R. and G.J.B.S.), and the procedures included levator resection or frontalis suspension, depending on levator excursion. Patients with good or moderate levator function (≥ 8 mm) underwent a levator resection or a Muller muscle-tarsus conjunctival resection (Fasanella-Servat procedure), whereas patients with poor levator function (< 4 mm) underwent frontalis suspension. Each unilateral ptotic operated eye was compared with its sound fellow eye.

FRONTALIS SUSPENSION: SURGICAL TECHNIQUE

A suture (alloplastic material or autogenous fascia lata) was passed in a closed cerclage-type fashion through skin entry (stab incisions) by way of supralash or eyebrow incision. Three stab incision sites that were approximately 5 mm apart were marked 3 mm above the lash line that was centered over the area of desired maximal elevation. Another two stab incision sites were marked above the eyebrow, approximately in line with the lateral and medial canthi. The suture was passed in a “double triangles” fashion via the supra-lash incisions and tied at the brow incisions. Stab incisions were sutured only at the eyebrow using interrupted sutures.

This retrospective study was approved by the local institutional review board.

STATISTICAL ANALYSIS

Statistical analysis was performed using a paired sample *t* test to compare preoperative and postoperative data, such as VA and refraction data, and to compare data between the operated and sound eye. Crosstabs and χ^2 analysis were used to calculate proportion differences for amblyopia between the ptotic and nonptotic fellow eye. Snellen VA was converted to a logMAR value. The statistical analysis was carried out using Microsoft Excel 2011 (Microsoft Corp, Redmond, Wash.) and IBM SPSS statistics software version 19.0 (SPSS Inc, Chicago, Ill.).

RESULTS

A total of 162 patients (92 males and 70 females; mean age \pm standard error: 10.37 ± 0.9 months [range 0.3–74 months, median 6 months]) underwent surgical ptosis repair in our institution during the study period. Almost three-quarters (74.1%, 120/162) had unilateral ptosis,

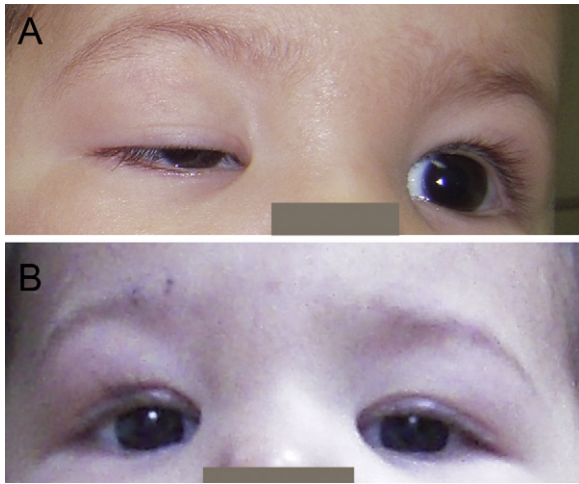


Fig. 1—Clinical image of a 1-year-old male before (A) and after (B) right upper eyelid frontalis suspension surgery using polytetrafluoroethylene (PTFE; Gore-Tex). Note good final eyelid position and contour.

and 25.9% (42/162) had bilateral ptosis. Amblyopia was present in 16% (26/162) of the patient population (of whom 42.2% [11/26] had concurrent strabismus), and 19.8% (32/162) had associated strabismus.

The types of surgeries that were performed included levator resection (47.5%, 77/162), frontalis suspension (46.3%, 75/162), and Fasanella-Servat (7.4%, 10/162). The frontalis suspension approach was subdivided into autologous fascia lata (40%, 30/75), silicone rod (29.3%, 22/75), Mersilene mesh (29.3%, 22/75), and polytetrafluoroethylene (PTFE; 1.3%, 1/75; Gore-Tex (W. L. Gore & Assoc, Flagstaff, Arizona)). Most patients achieved good functional and cosmetic outcome (Fig. 1).

Thirty-two patients (19.8%) needed reoperation, mostly for undercorrection and residual ptosis (Fig. 2). The reoperation rate was 10.4% (8/77) for the levator resection cases, 29.3% (22/75) for the frontalis suspension cases, 26.7% (8/30) for the autologous fascia lata cases, 27.3% (6/22) for the silicone rod cases, and 36.4% (8/22) for the Mersilene mesh cases. One fifth (2/10) of the Fasanella-Servat surgeries needed reoperation. Reoperation rate of 30% was mainly due to recurrent ptosis. No cases of suture exposure or infection were encountered. This may be because of the variety of alloplastic materials used: 22 surgeries with silicone rod, 22 with Mersilene mesh, and 1 case of PTFE (Gore-Tex).

A further analysis was carried out on the data of 27 patients with unilateral ptosis for whom there were complete preoperative and postoperative refractive records. They included 18 males (66.7%) and 9 females (33.3%) whose mean age at surgery was 3.75 ± 0.67 months (range 0.3–14 months). Twelve of them (44.4%) had anisometropia, and 9 (33.3%) had strabismus. Six patients (22.2%) had amblyopia on initial examination, of whom 2 also had strabismus and 2 also had anisometropia. All occurrences of amblyopia were on the ptotic

side, and there were no new cases of amblyopia diagnosed postoperatively. The mean preoperative VA in the ptotic eyes was 20/60, with a mean refraction SE of 1.62 ± 0.3 D. The mean cylinder at 0° was -0.19 ± 0.17 D, and the mean cylinder at 90° was -0.29 ± 0.1 D. The mean preoperative VA was 20/60, the mean SE was 1.54 ± 0.26 D, the mean cylinder at 0° was 0.4 ± 0.13 D, and the mean cylinder at 90° was -0.08 ± 0.06 D in the nonptotic fellow eyes. There were no significant differences between the values for the preoperative ptotic and nonptotic BCVA ($P = 0.66$), the SE ($P = 0.78$), and the mean cylinder at 90° ($P = 0.08$). The mean cylinder at 0° was, however, significantly different between the preoperative ptotic and nonptotic fellow eyes ($P = 0.03$), most probably as consequence of the gravitational pressure of the ptotic eyelid (Fig. 3). The surgeries performed for ptosis repair in this 27-patient subgroup were frontalis suspension in 18 (67%) and levator resection in 9 (33%). All patients achieved clearing of the visual axis without need for reoperation. The mean postoperative VA, SE, and mean cylinder at 90° remained unchanged after ptosis surgery. The mean cylinder at 0° changed from -0.34 D to $+0.36$ D ($P = 0.04$, paired sample t test), and the mean astigmatism correction by vector analysis after ptosis surgery was 1.10 ± 0.68 D. The mean follow-up for this group was 30 months (range 1–129 months).

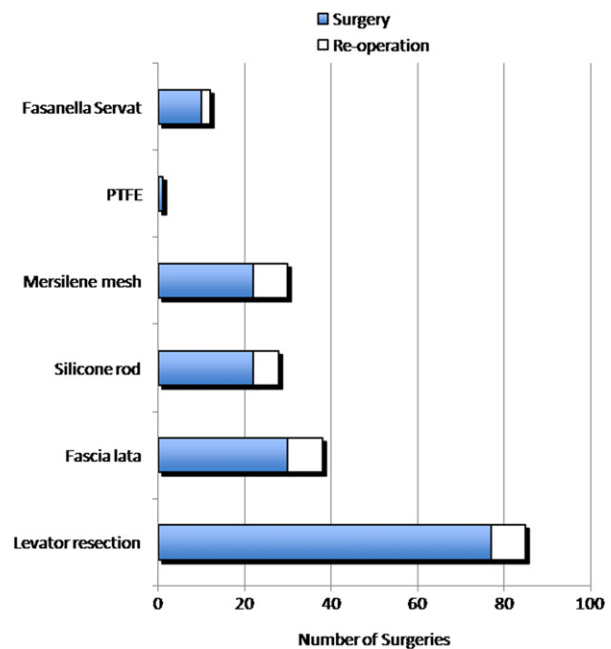


Fig. 2—Stacked bar diagram showing number of surgeries performed on 162 patients with congenital ptosis treated at the Goldschleger Eye Institute, Sheba Medical Center between January 1995 and November 2006, and the number of reoperations for residual ptosis in each group. PTFE, polytetrafluoroethylene.

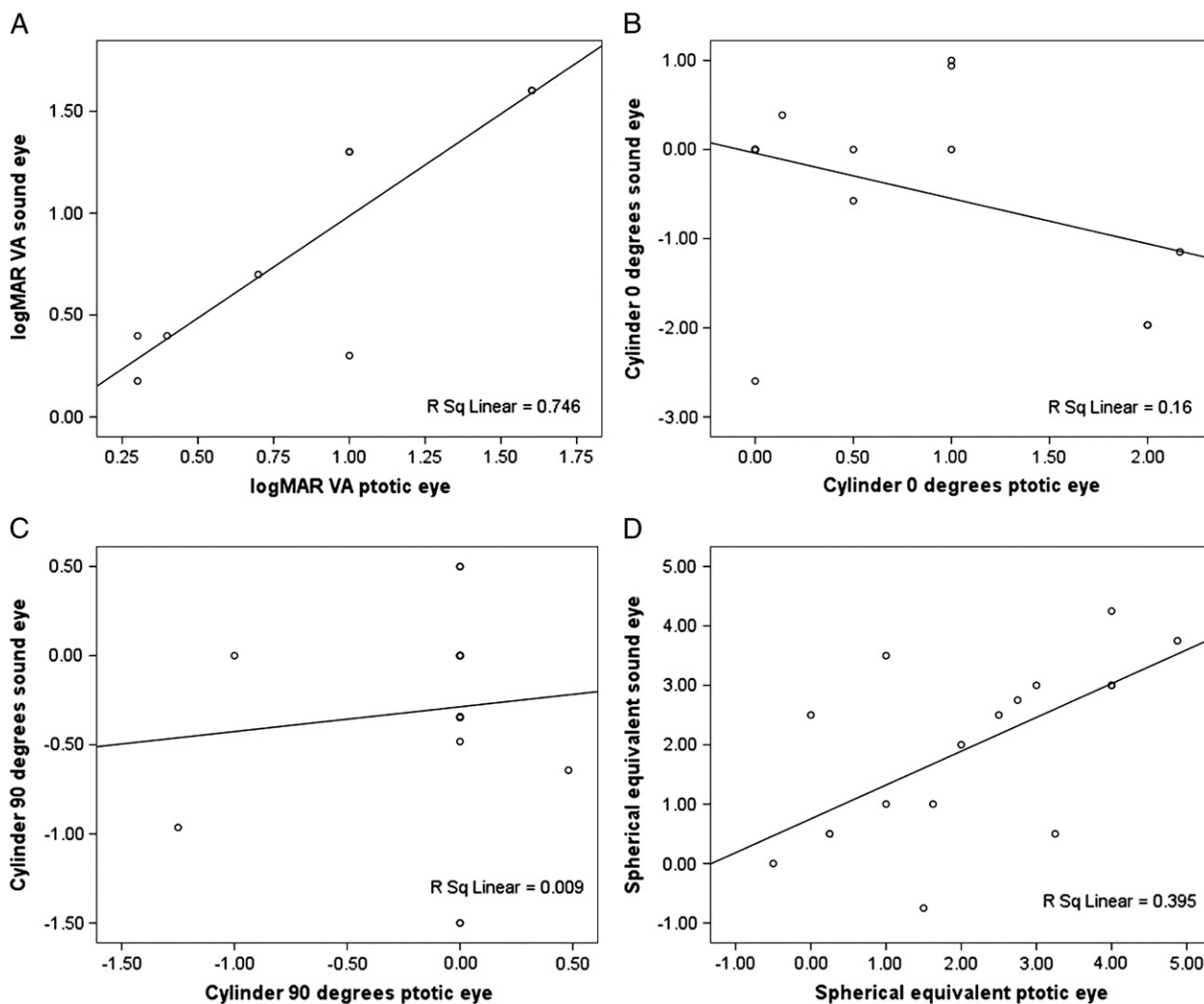


Fig. 3—A, Scatterplot describing preoperative logMAR visual acuity of ptotic eye (x axis) and sound (nonptotic) eye (y axis). B, Scatterplot describing preoperative cylinder at 0° in diopters of ptotic eye (x axis) and nonptotic eye (y axis). C, Scatterplot describing preoperative cylinder at 90° in diopters of ptotic eye (x axis) and nonptotic eye (y axis). D, Scatterplot describing preoperative spherical equivalent in diopters of ptotic eye (x axis) and nonptotic eye (y axis).

DISCUSSION

The most common treatment of congenital ptosis is surgical repair.⁹ The surgical approaches and timing vary, depending on ptosis severity and levator function. Ptosis severity is categorized as mild (≤ 2 mm), moderate (3 mm), or severe (≥ 4 mm). Levator function assessment is based on upper eyelid excursion and described as poor (≤ 4 mm), fair (5–7 mm), or good (≥ 8 mm). If there is no sign of developing amblyopia, the operation can usually be delayed until the child is 3 to 5 years old.¹⁰ At that age, the structures of the eyelid are better developed, and it is also possible to harvest autogenous fascia lata if necessary. If surgery is postponed, babies and toddlers should be monitored monthly to look for signs of amblyopia, worsening of ptosis, and development of abnormal head posture. When ptosis interferes with the child’s vision, however, surgery is recommended at an early age to prevent irreversible visual impairment.

Levator resection procedures are generally reserved for mild-to-moderate ptosis in which there is fair-to-good levator function.¹¹

Outcome studies for ptosis repair using the levator resection have described success rates ranging from 52% to 76%. Optimal outcomes, often classified as “good” or “successful,” are defined by ≤ 1 mm of postoperative ptosis, “fair” outcomes by > 1 mm of postoperative ptosis, and “poor” outcomes by > 1 mm of postoperative ptosis with poor cosmetic results. Lee et al.¹² reported good results in 69% (97/141) of congenital ptosis cases corrected by anterior levator resection. Berry-Brincat and Willshaw⁸ reported good results in 72% (88/122) of the eyes with congenital ptosis that underwent levator resection, and Cates and Tyers¹³ reported 100 congenital ptosis cases that underwent anterior levator resection, with good results in 76% of them at 6 weeks, followed by a decline to 74% at 6 months. Our findings correlate with these published values: The higher percentage of good

Table 1—Comparison of incidence of amblyopia in patients with ptosis

Study	Study patients (N)	Patients with amblyopia, n (%)
Anderson and Baumgartner (1980) ¹	123	25 (20)
Merriam et al. (1980) ³	65	9 (14)
Beneish et al. (1983) ¹⁷	55	12 (22)
Hornblase et al. (1995) ²	36	7 (19)
Dray and Leibovitch (2002) ⁴	130	30 (23)
Skaat et al. (this study)	162	26 (16)

results (89.6%) in our levator resection cases can probably be explained by the very small number of highly skilled surgeons who carried out the procedure.

In eyelids with very poor or no levator function, however, a frontalis sling procedure is often the only effective treatment. Numerous materials are used for slings, including silicone rods, Mersilene mesh, PTFE, and autogenous and banked fascia. Outcome studies using the frontalis sling procedure have described variable degrees of success, depending on the different materials used. PTFE and autogenous fascia have a reported recurrence rate between 4% and 20%, and nylon and silicone have reported recurrence rates between 40% and 100%.¹⁴ It is generally accepted that suture material serves only as a temporary skeleton for scar formation; therefore, no difference is anticipated between different suture materials as long as they remain in proper position during the inflammation and scarring processes. Better cosmetic outcome was, however, noted in cases in which a nylon sling was used.¹⁴ Several suture designs, such as single-loop or double-pentagon configurations, are used for frontalis suspension surgery, with no clinically significant difference between them.¹⁴

Many investigators believe that all cases of congenital ptosis that are treated with frontalis suspension will eventually recur. This is evident from the greater recurrence rate (ranging from 4% to 100%) published in studies with relatively longer follow-up periods,¹⁵ regardless of the type of sling used. In cases of congenital ptosis, parents and children should realize that the recurrence rate is high after surgery and that the patient is likely to require additional procedures.

Despite the fact that autogenous fascia has better biocompatibility than alloplastic materials, similar functional and cosmetic outcomes and incidence of ptosis recurrence may be achieved with the latter.¹⁶ Complications commonly associated with frontalis suspension include early postoperative exposure keratopathy, inflammation or pyogenic granuloma, eyebrow scars, suture infection with preseptal cellulitis, and suture exposure, and their rates vary with different sling materials. Specifically, greater rates of complications have been associated with nylon monofilament and PTFE.

The correlation between congenital ptosis and amblyopia continues to be a matter of controversy. The incidence rate of amblyopia in the general population is estimated to be

approximately 3%.¹⁷ Previous studies have reported the incidence of amblyopia in patients with congenital ptosis (Table 1), and they are in agreement that there is a greater incidence in patients with congenital ptosis compared with the general population. The incidence rate of amblyopia in this study was 22.2% (6 of the 27 children in our subgroup). This figure correlates with the estimates reported in the literature. The questions of whether ptosis alone may cause amblyopia and whether conditions such as anisometropia and strabismus result from or are simply associated with congenital ptosis remain unanswered.²

We evaluated the anisometric changes after surgical repair of ptosis with the intent of determining the potential contribution of anisometropia to the development of refractive amblyopia. There are only a few studies on this issue in the literature. Hornblase et al.² found that only 1 of their 6 patients without amblyopia experienced development of anisometropia after surgical repair of ptosis but did not experience development of postoperative amblyopia. Klimek et al.¹⁸ reported a significant cylindrical change (≥ 0.75 D) in eyes that underwent levator resection for unilateral congenital ptosis, although they found no significant differences when refractive errors were compared interocularly. In contrast, Berry-Brincat and Willshaw⁸ reported an incidence rate of 18.7% among the patients who had a significant refractive error requiring spectacles after surgical repair of ptosis, with anisometropia present in more than 72% of them.

In our study, 2 of 6 cases of amblyopia were attributed to strabismus, another 2 could be attributed to the anisometric changes, and the remaining 2 had no apparent cause other than the ptotic lid itself. These results are in correlation to those of previous studies^{2,4} that found an incidence rate between 6% and 6.9% (2 and 7 patients, respectively) to be attributed to deprivation of visual stimuli alone.

We did not find any significant differences in VA, SE, or mean cylinder at 90° between the ptotic eyes before and after surgery compared with the nonptotic fellow eyes. This suggests that although there had been minimal anisometric changes after surgery, they were not sufficient to influence the VA and SE or to contribute to the development of refractive amblyopia.

The surgical procedures performed in this study varied according to the preference of the individual surgeon. Frontalis suspension procedures were generally used for cases with poor levator function and severe ptosis, whereas levator resection was preferred for moderate-to-severe ptosis with fair levator function.

In conclusion, although our study is limited because of its retrospective design, our results suggest that surgical correction of congenital ptosis is effective with good functional and cosmetic outcome, and aids the treatment of amblyopia more by alleviating stimulus deprivation and less as a consequence of anisometric changes. We acknowledge that a subgroup of 27 patients is too small to

make conclusions concerning the effect of ptosis surgery or astigmatism, or the effect of the ptotic lid on astigmatism compared with the normal lid. It may be that with larger groups more significant *P* values were calculated. Larger studies are needed to evaluate the relationship among unilateral congenital ptosis, induced astigmatism, amblyopia, and ptosis correction.

Disclosure: The authors have no proprietary or commercial interest in the materials discussed in this article.

Supported by: Talpiot Medical Leadership Program, Sheba Medical Center, Tel Hashomer, Israel.

REFERENCES

1. Anderson RL, Baumgartner SA. Amblyopia in ptosis. *Arch Ophthalmol*. 1980;98:1068-9.
2. Hornblass A, Kass LG, Ziffer AJ. Amblyopia in congenital ptosis. *Ophthalmic Surg*. 1995;26:334-7.
3. Merriam WW, Ellis FD, Helveston EM. Congenital blepharoptosis, anisometropia, and amblyopia. *Am J Ophthalmol*. 1980;89:401-7.
4. Dray JP, Leibovitch I. Congenital ptosis and amblyopia: a retrospective study of 130 cases. *J Pediatr Ophthalmol Strabismus*. 2002;39:222-5.
5. Lin LK, Uzcategui N, Chang EL. Effect of surgical correction of congenital ptosis on amblyopia. *Ophthalm Plast Reconstr Surg*. 2008;24:434-6.
6. Broniarczyk-Loba A, Iljin A, Nowakowska O, Zieliński A, Omulecki W. Congenital blepharoptosis: part II. Visual disorders coexisting with congenital blepharoptosis. *Acta Chir Plast*. 2003;45:13-5.
7. Kumar S, Chaudhuri Z, Chauhan D. Clinical evaluation of refractive changes following brow suspension surgery in pediatric patients with congenital blepharoptosis. *Ophthalmic Surg Lasers Imaging*. 2005;36:217-27.
8. Berry-Brincat A, Willshaw H. Paediatric blepharoptosis: a 10-year review. *Eye (Lond)*. 2009;23:1554-9.
9. Iliff JW, Pacheco EM. Ptosis surgery. In: Tasman W, Jaeger EA, editors. *Duane's Clinical Ophthalmology*. Philadelphia: Lippincott Williams and Wilkins; 2001. p. 1-18.
10. Finsterer J. Ptosis: causes, presentation, and management. *Aesthetic Plast Surg*. 2003;27:193-204.
11. Harvey DJ, Iamphongsai S, Gosain AK. Unilateral congenital blepharoptosis repair by anterior levator advancement and resection: an educational review. *Plast Reconstr Surg*. 2010;126:1325-31.
12. Lee V, Konrad H, Bunce C, Nelson C, Collin JR. Aetiology and surgical treatment of childhood blepharoptosis. *Br J Ophthalmol*. 2002;86:1282-6.
13. Cates CA, Tyers AG. Outcomes of anterior levator resection in congenital blepharoptosis. *Eye (Lond)*. 2001;15:770-3.
14. Ben Simon GJ, Macedo AA, Schwarcz RM, et al. Frontalis suspension for upper eyelid ptosis: evaluation of different surgical designs and suture material. *Am J Ophthalmol*. 2005;140:877-85.
15. Skaat A, Ben Simon G. Evaluation and management of blepharoptosis. Comparison of techniques and clinical outcomes. In: Cohen AJ, Weinberg DA, editors. *Blepharoptosis: Diagnosis and Management*. New York: Springer-Verlag; 2011. p. 263-8.
16. Wilson ME, Johnson RW. Congenital ptosis. Long-term results of treatment using lyophilized fascia lata for frontalis suspensions. *Ophthalmology*. 1991;98:1234-7.
17. Beneish R, Williams F, Polomeno RC, Little JM, Ramsey B. Unilateral congenital ptosis and amblyopia. *Can J Ophthalmol*. 1983;18:127-30.
18. Klimek DL, Summers CG, Letson RD, Davitt BV. Change in refractive error after unilateral levator resection for congenital ptosis. *J AAPOS*. 2001;5:297-300.