

carcinoid tumor. The intraocular tumor continued to grow despite chemotherapy with carboplatin and etoposide.

In June 2000, a second, flat choroidal tumor measuring 5×4 mm in basal dimensions was identified in the right eye along the inferotemporal arcade, 6 mm from the fovea (Figure 2, A). Despite bilateral external beam radiotherapy in November 2000, both tumors continued to enlarge. By July 2002, the visual acuity in the left eye dropped to light perception. In November 2002, the tumor in the right eye enlarged to 15×9 mm in basal dimensions and 4.8 mm in thickness, and had encroached to within 3 mm of the fovea (Figure 2, B). The right eye visual acuity declined to 20/60, with a shallow exudative retinal detachment extending into the fovea and a more bullous detachment developing inferiorly. A fluorescein angiogram demonstrated marked intratumoral vascularity (Figure 2, C).

Because the tumor had failed chemotherapy and radiation, PDT was attempted according to an institutional review board-approved protocol. Intravenous verteporfin (6 mg/m^2) was infused over 10 minutes, and 689 nm light was delivered by an ocular photoactivation diode and laser link slit lamp (Coherent, Palo Alto, California). Three overlapping spots (8 mm diameter) were each delivered over 83 seconds (Figure 2, D). One week later, a limited serous choroidal detachment developed in the nasal periphery but resolved on a regimen of oral corticosteroids. Within 2 months, the tumor regressed by 33% in basal area and 25% in height, the exudative retinal detachment resolved, and the visual acuity returned to 20/40 (Figure 2, E and F). The patient remained stable for 2 months but died before returning for further follow-up.

The presentation in this patient was typical for choroidal metastasis from carcinoid tumor,³ which is often resistant to chemotherapy and radiation. We elected to treat the highly vascular tumor with PDT because this modality induces intraluminal photothrombosis in endothelium-line structures.⁴ This rationale was supported by previous success using PDT to treat choroidal hemangioma, another vascular choroidal tumor.⁵ Because long-term follow-up was precluded by the patient's death, it is possible that the tumor may have recurred at some point. However, our experience with this patient suggests that PDT may be a reasonable palliative therapy for selected patients with metastatic choroidal tumors.

REFERENCES

1. Ferry AP, Font RL. Carcinoma metastatic to the eye and orbit. I. A clinicopathologic study of 227 cases. *Arch Ophthalmol* 1974;92:276–286.
2. Augsburger JJ, Guthoff R. Metastatic cancer to the eye. In: Yanoff M, Duker JS, editors. *Ophthalmology*. 2nd ed. St. Louis: Mosby, 2003:1064–1069.
3. Harbour JW, De Potter P, Shields CL, Shields JA. Uveal metastasis from carcinoid tumor. Clinical observations in nine cases. *Ophthalmology* 1994;101:1084–1090.
4. Kramer M, Miller JW, Michaud N, et al. Liposomal benzo-

porphyrin derivative verteporfin photodynamic therapy. Selective treatment of choroidal neovascularization in monkeys. *Ophthalmology* 1996;103:427–438.

5. Sheidow TG, Harbour JW. Photodynamic therapy for circumscribed choroidal hemangioma. *Can J Ophthalmol* 2002;37:314–317.

Extraocular Muscle Enlargement With Tendon Involvement in Thyroid-associated Orbitopathy

Guy J. Ben Simon, MD, Hasan M. Syed, Raymond Douglas, MD, PhD, John D. McCann, MD, PhD, and Robert A. Goldberg, MD

PURPOSE: To evaluate the configuration of extraocular muscle and tendon enlargement in patients with thyroid-associated orbitopathy (TAO).

DESIGN: Retrospective, noncomparative case series.

METHODS: We retrospectively evaluated the preoperative computed tomography (CT) or magnetic resonance imaging (MRI) scans, or both, of 125 consecutive patients with previously diagnosed TAO. Axial CT ($n = 88$) or MRI ($n = 37$) slices of the orbits were examined for tendon involvement of enlarged medial or lateral recti muscles. A ratio of tendon to muscle width greater than 0.5 was considered as tendon involvement.

RESULTS: Eight patients (6.4%) with TAO demonstrated tendon involvement on axial CT or MRI. These patients had significantly greater diplopia in primary gaze than patients with no tendon involvement or patients with no muscle enlargement.

CONCLUSION: The configuration of extraocular muscle enlargement on imaging studies has traditionally been used to differentiate TAO from other inflammatory processes because the tendon is typically spared (fusiform configuration) in TAO. However, we found that the configuration of tendon involvement (cylindrical configuration) can occasionally be noted in TAO and may be more frequently associated with primary gaze diplopia. Tendon involvement does not eliminate the diagnostic possibility of TAO. (*Am J Ophthalmol* 2004;137:1145–1147. © 2004 by Elsevier Inc. All rights reserved.)

Accepted for publication Jan 2, 2004.

From the Division of Orbital and Ophthalmic Plastic Surgery, Department of Ophthalmology, Jules Stein Eye Institute, David Geffen School of Medicine, University of California at Los Angeles, Los Angeles, California.

Inquiries to Guy J. Ben Simon, MD, Jules Stein Eye Institute, 100 Stein Plaza, Box 957006, Los Angeles, CA 90095-7006; fax: (310) 825-9263; e-mail: simon@jsei.ucla.edu

TABLE 1. Patient Demographics and Imaging Characteristics

	Mean ± SD (range)
Age (yr)	52 ± 12 (21-82)
Male/female	29 males/96 females
Duration of orbitopathy and/or eye symptoms (yr)*	6 ± 8 (0-32)
Bilateral disease (n, %)	115 (92)
Pattern of muscle involvement by CT/MRI (n, %) [†]	
1. Fusiform sparing tendon	42 (33.6)
2. Fusiform involving tendon	5 (4)
3. Cylindrical sparing tendon	47 (37.6)
4. Cylindrical involving tendon	3 (2.4)
5. Nodular	2 (1.6)
6. No muscle enlargement	26 (20.8)
Horizontal diplopia in primary position of gaze (n, %)	32 (25.6)

Abbreviations: CT = computerized tomography, MRI = magnetic resonance imaging.

*Length of time noted in medical chart from when patients first noted eye symptoms (chemosis, double vision, proptosis) or were diagnosed with thyroid-associated orbitopathy till CT/MRI was done.

[†]Extraocular muscle enlargement configuration according to the description by Patrinely et al³.

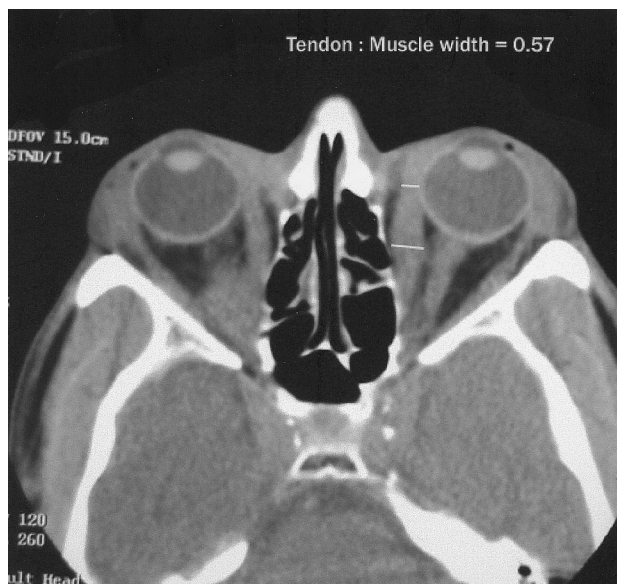


FIGURE 1. Moderate involvement of muscle tendon on computed tomography scan of a patient with thyroid-associated orbitopathy (fusiform enlargement, tendon/muscle ratio 0.57).

TENDON-SPARING EXTRAOCULAR MUSCLE ENLARGEMENT is considered pathognomonic for thyroid-associated orbitopathy (TAO), whereas tendon involvement is thought to be more characteristic of idiopathic orbital

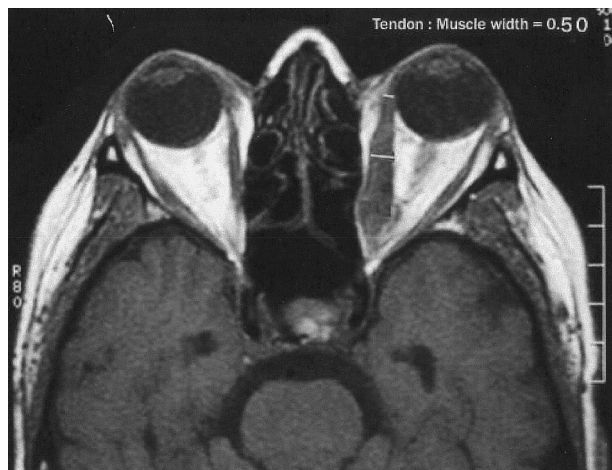

FIGURE 2. Moderate to severe involvement of muscle tendon on magnetic resonance imaging scan of a patient with thyroid-associated orbitopathy (fusiform enlargement, tendon/muscle ratio 0.50).

inflammation (orbital pseudotumor or orbital myositis). The purpose of this study was to investigate the reliability of tendon involvement as a diagnostic indicator of non-TAO muscle enlargement.¹⁻³

We retrospectively evaluated computed tomography (CT) or magnetic resonance imaging (MRI) scans, or both, of 125 consecutive patients with previously diagnosed TAO who were seen at the Jules Stein Eye Institute Orbital and Ophthalmic Plastic Surgery outpatient clinics. Clinical characteristics were abstracted from medical records and tabulated (Table 1). Thyroid-associated orbitopathy was diagnosed by the presence of eyelid retraction and congestion or proptosis, combined with laboratory evidence of Graves disease. Axial slices of CT (88 patients) or MRI (37 patients) of the orbits were examined for tendon involvement in enlarged medial or lateral recti muscles. The image slice that included the lens bilaterally was used. The muscle was designated as enlarged if it was larger than the optic nerve. The study complied with the policies of the local institutional review board.

The morphology of the extraocular muscle was qualitatively assessed and classified using the same definition of tendon involvement morphology according to work by Patrinely and associates.³ Muscle involvement was classified according to one of five possible configurations: (1) fusiform sparing the tendon; (2) fusiform involving the tendon; (3) cylindrical sparing the tendon; (4) cylindrical involving the tendon; and (5) nodular. In the absence of muscle enlargement none of the categories were assigned. On a computer display, the tendon width was measured at the globe equator, and muscle belly width was measured at the midpoint. The tendon was designated as enlarged if the ratio of tendon to muscle belly width was greater than 0.5. Two independent observers (G.B.S. and

R.A.G.) reviewed the imaging studies, but were not masked.

One hundred twenty-five consecutive cases of TAO (29 male, 96 female; mean age 53 ± 12 years) were evaluated. Ninety-two percent of the patients had bilateral enlargement of the horizontal rectus muscles. Data are summarized in Table 1.

The most common configurations of tendon-sparing muscle enlargement were cylindrical (37.6% of scans) and fusiform patterns (33.6%). Eight TAO patients (6.4%) in our series had muscle enlargement involving the tendon by CT (six) or MRI (two): five (4%) with fusiform pattern (Figures 1 and 2) and three (2.4%) with cylindrical enlargement. Patients with tendon involvement tended to be older (60 versus 52 years, $P = .009$, independent samples t test). Four patients (50%) in this group were males, compared with 25 (21.4%) in the tendon-sparing group ($P = .06$, χ^2).

There was a statistically significant increased incidence in primary gaze horizontal diplopia in patients with tendon involvement: 37.5% of the patients with tendon involvement had diplopia in primary gaze, compared with 25.3% of the patients with tendon-sparing muscle enlargement ($P < 0.001$, χ^2) and 15.4% of the patients with no muscle enlargement ($P < 0.001$).

In our study population we noted eight patients (6.4%) who by CT or MRI demonstrated some degree of tendon involvement, a finding contrary to the generally accepted description of the tendon-sparing nature of TAO. An investigation of the frequency of radiographic tendon involvement in TAO has not been reported previously. We also noted that there was a significantly higher frequency of primary gaze horizontal diplopia in the enlarged tendon group relative to the tendon-sparing and nonmuscle-involving groups.

Our study is limited by small size and a retrospective data set, and a better-controlled prospective study would provide a more accurate representation of the frequency of tendon involvement in TAO. Although none of the patients with TAO had typical features of myositis, such as stuttering involvement of multiple muscles and rapid response to corticosteroids, there is a possibility that myositis coexisted with TAO in some of our patients, and this could compromise the validity of our conclusions.

Extraocular muscle enlargement occurs in a variety of orbital diseases such as idiopathic orbital inflammation (pseudotumor), arteriovenous malformations or fistula, acromegaly, and neoplasia. Graves disease is the most common cause of extraocular muscle enlargement. In the description of CT characteristics of extraocular muscles in TAO, Rothfus and Curtin² noted fusiform expansion, uniform enhancement, and sharp delineation of muscle bellies tapering into tendons. Rothfus and Curtin also stated that affected tendons in TAO never reach the degree of thickening seen in myositis.²

The study by Patrinely and associates³ of muscle and tendon involvement in non-Graves cases revealed heterogeneous morphology. In their study of 15 cases of orbital inflammatory diseases, they found 40% bilateral involvement in inflammatory cases and only 47% tendon involvement. Orbital imaging studies are useful in TAO and other inflammatory orbital diseases to exclude mimicking disorders such as focal neoplasia, contiguous infection, or inflammation from adjoining sinuses or cranial cavities. However, the findings in the study by Patrinely and associates³ and in the current study remind us that the morphology of muscle enlargement, while suggestive, cannot be relied upon to definitively establish the subtype of orbital inflammatory diseases, such as myositis or TAO. Although the tendon is frequently involved in cases of myositis, it may be spared. Conversely, although the tendon is usually spared in TAO, it may occasionally be involved—so this finding on the imaging studies does not preclude the diagnosis of TAO.

REFERENCES

1. Bahn RS, Heufelder AE. Pathogenesis of Graves' ophthalmopathy. *N Engl J Med* 1993;329:1468–1475.
2. Rothfus WE, Curtin HD. Extraocular muscle enlargement: a CT review. *Radiology* 1984;151:677–681.
3. Patrinely JR, Osborn AG, Anderson RL, Whiting AS. Computed tomographic features of nonthyroid extraocular muscle enlargement. *Ophthalmology* 1989;96:1038–1047.

Conjunctival Melanoma Metastasis Diagnosed by Sentinel Lymph Node Biopsy

Michael Barody, MD, John B. Holds, MD, Mimi S. Kokoska, MD, and James Boyd, MD

PURPOSE: Evaluate the use of sentinel lymph node biopsy (SLNB) in staging and directing treatment of patients with conjunctival malignancy.

DESIGN: Retrospective, noncomparative, interventional case reports.

METHODS: Two patients with conjunctival melanoma underwent SLNB, which consisted of lymphoscintigraphy with injection of sulfur colloid technetium-99m. Lymphazurin blue was injected intraoperatively into the area of prior excision. The combination of a signal

Accepted for publication Jan 2, 2004.

From the Department of Surgery, Division of Plastic Surgery, Pennsylvania State College of Medicine, Milton S. Hershey Medical Center, Hershey, Pennsylvania; Department of Ophthalmology, Saint Louis University, St. Louis, Missouri; Department of Otolaryngology—Head and Neck Surgery, University of Arkansas for Medical Sciences and John L. McClellan Memorial Veterans Hospital, Little Rock, Arkansas; and Department of Otolaryngology—Head and Neck Surgery, Saint Louis University, St. Louis, Missouri.

Inquiries to John B. Holds, MD, 450 N New Ballas Rd, No 266, St. Louis, MO 63141; fax: (314) 567-6575; e-mail: eyelidmd@hotmail.com