

# Transconjunctival Müller Muscle Recession With Levator Disinsertion for Correction of Eyelid Retraction Associated with Thyroid-Related Orbitopathy

GUY J. BEN SIMON, MD, AHMAD M. MANSURY, BS, ROBERT M. SCHWARCZ, MD, SARA MODJTAHEDI, BS, JOHN D. McCANN, MD, PhD, AND ROBERT A. GOLDBERG, MD

• **PURPOSE:** To evaluate the efficacy of transconjunctival Müller muscle recession and graded levator disinsertion for eyelid retraction in patients with thyroid-related orbitopathy (TRO).

• **DESIGN:** Retrospective consecutive case series.

• **METHODS:** Medical record review of 78 TRO patients (107 eyelids) who underwent surgery for upper eyelid retraction in a 5-year period was performed. Main outcome measures were anatomic and functional success, minimal reflex distance (MRD), lagophthalmos, eyelid asymmetry, and patient discomfort.

• **RESULTS:** One hundred seven eyelid retraction surgeries were performed on 78 TRO patients (63 women, mean age 49 years); mean follow-up time was 16.7 months. Upper eyelid position, lagophthalmos, exposure keratopathy, and patients' discomfort markedly improved after surgery ( $P < .001$ ). Marginal reflex distance (MRD1) decreased an average of 2.6 mm from 6 mm pre-operatively to 3.4 mm post-operatively ( $P < .001$ ); lagophthalmos decreased an average of 0.6 mm from 1.3 mm pre-operatively to 0.4 mm post-operatively ( $P = .006$ ). Failure rate was 8.4%, most improved with a second surgery. Overcorrection was noticed in three cases (2.8%). Eyelid asymmetry improved from a mean of 1.0 mm pre-operatively to 0.4 mm post-operatively ( $P = .001$ ); more than 80% of patients showed eyelid asymmetry of 1 mm or less.

• **CONCLUSION:** Transconjunctival Müller muscle and levator recession is safe and effective in correction of mild, moderate, or severe eyelid retraction in TRO

patients. The failure rate is less than 10% and may be addressed by a second surgery. (*Am J Ophthalmol* 2005;140:94–99. © 2005 by Elsevier Inc. All rights reserved.)

**T**HYROID-RELATED ORBITOPATHY (TRO) IS MANIFESTED in 25% to 50% of patients with Graves disease. Some suffer mild ocular discomfort from eyelid retraction, proptosis, and orbital congestion; others may experience a more debilitating disease with long-term sequelae caused by exposure keratopathy or compressive optic neuropathy with visual loss.<sup>1–6</sup>

Upper eyelid retraction is the most common sign of Graves or TRO<sup>7</sup> and may be associated with overactivity of the sympathetically innervated Müller muscle.<sup>8</sup> Along with its cosmetically unacceptable appearance because of the typical stare, patients suffer from corneal and conjunctival exposure and decreased vision. Several treatment options have been described for correction of eyelid retraction, including topical guanethidine,<sup>9</sup> Botulinum toxin type A injections,<sup>10,11</sup> Müller muscle recession,<sup>12</sup> recession of the levator muscle through eyelid crease incision,<sup>13</sup> marginal myotomies,<sup>14</sup> full thickness graded blepharotomy, as well as the introduction of an upper eyelid spacer in cases of severely debilitating eyelid retraction.<sup>15–17</sup>

The purpose of this study was to describe the safety and efficacy of transconjunctival Müller muscle recession with or without levator muscle recession in 78 TRO patients at the Jules Stein Eye Institute.

## METHODS

A RETROSPECTIVE MEDICAL RECORD REVIEW OF ALL TRO patients who underwent surgery for upper eyelid retraction

Accepted for publication Feb 14, 2005.

From the Division of Orbital and Ophthalmic Plastic Surgery, Jules Stein Eye Institute and Department of Ophthalmology, David Geffen School of Medicine at UCLA, Los Angeles, California.

Inquiries to Guy J. Ben Simon, MD, Jules Stein Eye Institute, 100 Stein Plaza, Los Angeles, CA 90095–7006; Fax (310) 825-9263; e-mail: guybensimon@gmail.com

between January 1999 and December 2003 was performed. The data retrieved included age, gender, duration of TRO, type of surgery, pre-operative and post-operative digital photographs, visual acuity (VA), intraocular pressure (IOP), exophthalmos, marginal reflex distance (MRD1), lagophthalmos, exposure keratopathy, and related complications. The study complied with the policies of the local institutional review board.

Grading of eyelid retraction was performed according to the severity of upper eyelid retraction measured by the marginal reflex distance MRD1—the distance from the pupillary light reflex to the margin of the upper eyelid. MRD1 of 5 mm or less was graded as mild eyelid retraction, MRD1 > 5 mm and <7 mm as moderate retraction, and MRD1 > 7 mm as severe upper eyelid retraction. The study was approved by the local institutional review board.

- **SURGICAL TECHNIQUE:** Written informed consent was obtained from all patients. The upper eyelid was infiltrated with lidocaine 2% with 1:100,000 epinephrine. The eyelid was next everted using a Desmarres retractor, and an additional sub-conjunctival injection of local anesthesia was then given. A conjunctival incision was carried out at the superior tarsal edge using hot tip cautery or a number 15 blade. Meticulous dissection was performed to separate Müller muscle from the underlying conjunctiva and the levator aponeurosis. Separation of Müller muscle from the conjunctiva was sometimes facilitated with hydrodissection and transillumination. Müller muscle was excised with an attempt at total excision and the eyelid replaced to its normal position. When deemed necessary, graded recession of the levator aponeurosis was achieved using the same transconjunctival incision. In cases of lateral flare, dissection was carried out toward the orbital rim and accompanied by spreading of the levator aponeurosis fibers. The described maneuvers were repeated until a desired correction of upper eyelid retraction was achieved. The conjunctival incision was left unsutured. In cases of bilateral eyelid retraction, the procedures were performed simultaneously until achieving desired symmetry and upper eyelid position.

- **STATISTICAL ANALYSIS:** Statistical analysis was performed using paired sample *t* tests to evaluate pre-operative and post-operative data such as VA, IOP, exophthalmometry measurements, lagophthalmos, and MRD1 measurements. One-sample *t* test was used to evaluate the change ( $\Delta$ ) in pre-operative and post-operative data (VA, IOP, exophthalmos, MRD1, lagophthalmos). Pearson bivariate correlation was used to examine influence of age, VA, IOP, and extent of exophthalmos and treatment outcome.  $\chi^2$  and cross-tabs analyses were used to explore the difference in proportions of patients with eyelid retraction, lagophthalmos, and exposure keratopathy pre-operatively and post-operatively. Patients with eyelid retraction were categorized according to post-operative results (improvement

vs unchanged or worsening) for proportion calculations. Statistical analysis was performed with Microsoft Excel (Microsoft Corporation, Redmond, Washington) and SPSS (SPSS, Chicago, Illinois) programs. Conversion of Snellen acuity to logarithm of the minimum angle of resolution values (logMAR) was performed.

## RESULTS

SEVENTY-EIGHT TRO PATIENTS (15 MEN, 63 WOMEN, MEAN age  $49 \pm 13$  years) with unilateral or bilateral upper eyelid retraction underwent surgery for correction of eyelid retraction. Twenty-nine patients (37%) underwent bilateral surgery. Overall, 107 eyelid retraction surgeries were performed; of these 16 (15%) were Müller muscle recession alone and 91 (85%) were Müller muscle recession with levator disinsertion. Age, gender, and duration of TRO were not associated with severity of eyelid retraction.

Table 1 summarizes pre-operative and post-operative data for our study population. Pre-operatively, 88 cases (82%) had mild eyelid retraction (<5 mm), 16 cases (15%) had moderate retraction, (5 to 7 mm) and 3 cases (3%) had severe eyelid retraction (>7 mm). Post-operatively, 86 cases (80%) showed normal eyelid position, and 21 (20%) had mild residual eyelid retraction (Figure 1). Overcorrection and post-operative eyelid ptosis was noted in three cases (2.8%).

Most of the patients (91%) improved after surgery, and only 10 patients (9%) remained unchanged or slightly worsened following surgery ( $P < .001$ ,  $\chi^2$ ; Figures 2 to 4.) A higher percentage of improvement was observed in men, smokers, patients suffering hypertension ( $P < .001$ ,  $\chi^2$ ), and those with more severe eyelid retraction ( $r = 0.45$ ,  $P < .005$ , Pearson correlation). Müller muscle recession was effective in treating exposure keratopathy. Post-operatively only 9% of operated eyes showed evidence of punctate keratopathy compared with 32% pre-operatively ( $P < .001$ ,  $\chi^2$ ). Pre-operative symptoms of ocular discomfort, foreign body sensation, tearing, or light sensitivity improved in all patients who displayed overall satisfactory surgical outcomes.

MRD1 decreased an average of  $2.6 (\pm 1.6)$  mm from  $6 (\pm 1.9)$  mm pre-operatively to  $3.4 (\pm 1.6)$  mm post-operatively ( $P < .001$ ); lagophthalmos decreased an average of  $0.6 (\pm 1.3)$  mm from  $1.3 (\pm 1.5)$  mm pre-operatively to  $0.4 (\pm 0.9)$  mm post-operatively ( $P = .006$ ).

Eyelid asymmetry defined as absolute height difference between both upper eyelids improved from a mean of  $1.0 (\pm 1.5)$  mm pre-operatively to  $0.4 (\pm 0.6)$  mm post-operatively ( $P = .001$ , paired samples *t* test). Post-operatively 82% of patients had an upper eyelid difference of 1 mm

**TABLE.** Pre-operative and Post-operative Data for Thyroid-Related Orbitopathy (TRO) Patients Undergoing Müller Muscle Recession With or Without Levator Disinsertion for Eyelid Retraction in a 5-Year Period

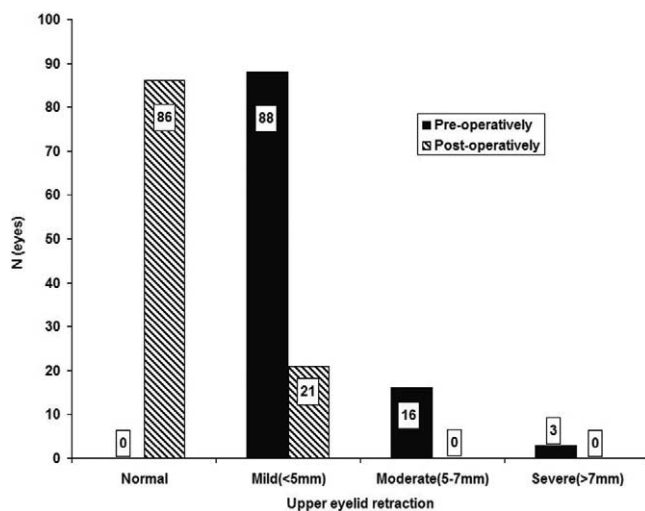
	Pre-operative	Post-operative	P*
Mean visual acuity	20/25	20/25	NS
Eyelid retraction (mm)			
Normal (0)	0 (0%)	86 (80%)	
Mild (<5 mm)	88 (82%)	21 (20%)	<.001
Moderate (5–7 mm)	16 (15%)	0 (0%)	
Severe (>7 mm)	3 (3%)	0 (0%)	
MRD (mm)	6 ± 1.9	3.4 ± 1.6	<.001
Eyelids asymmetry (mm) <sup>†</sup>	1.0 ± 1.5	0.4 ± 0.6	.001
Lagophthalmos (mm)	1.3 ± 1.5	0.7 ± 0.9	.006
Exposure keratopathy (n)	34 (32%)	9 (8.4%)	<.001
Follow-up (mo)	16.7 ± 15 (6–84)		

N = 78 patients, 107 eyes.

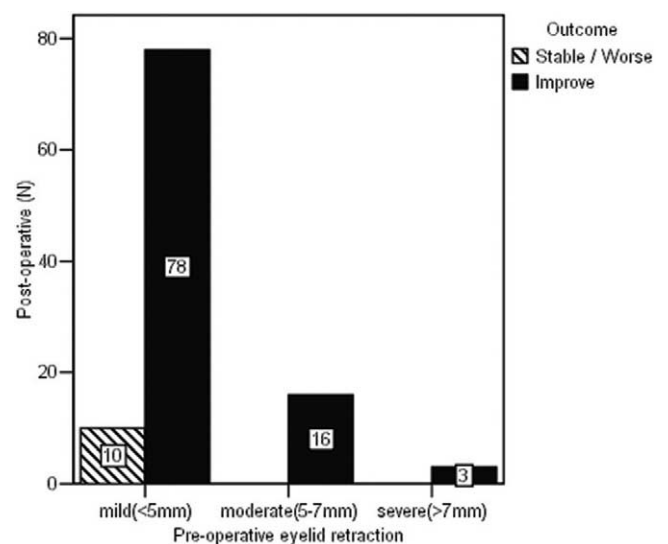
MRD = margin reflex distance, measured from the inferior border of the upper eyelid to the corneal light reflex.

\*Calculations of P values: paired samples t test and one-sample t test (after calculating delta values) were used for calculating pre-operative and post-operative visual acuity, MRD, and lagophthalmos differences.  $\chi^2$  and cross-tabs analyses were used to calculate change in eyelid position status after surgery.

<sup>†</sup>Eyelid asymmetry was calculated as the absolute difference between both upper eyelids height (MRD) pre-operatively and post-operatively.



**FIGURE 1.** Post-operative eyelid position after Müller muscle recession with or without levator disinsertion in 107 thyroid-related orbitopathy (TRO) cases operated for eyelid retraction in a 5-year period. Mean age of patients was 49 ( $\pm$  13) years. Most cases showed no evidence of eyelid retraction after surgery. More than 80% of patients showed an eyelid asymmetry of 1 mm or less post-operatively.

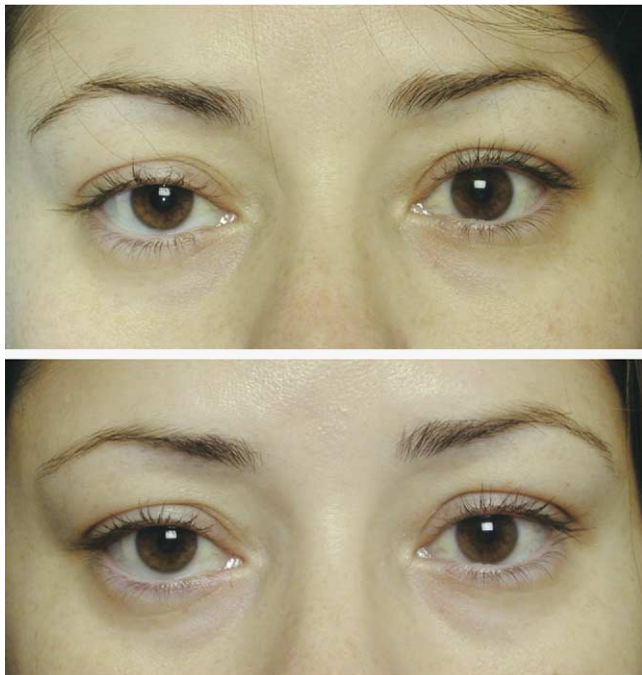

**FIGURE 2.** Outcome of 107 surgeries for eyelid retraction in TRO patients in a 5-year period. Patients were assigned as improved if they achieved a better post-operative eyelid position and as unchanged or worsened if eyelid position did not change or worsened with surgery.

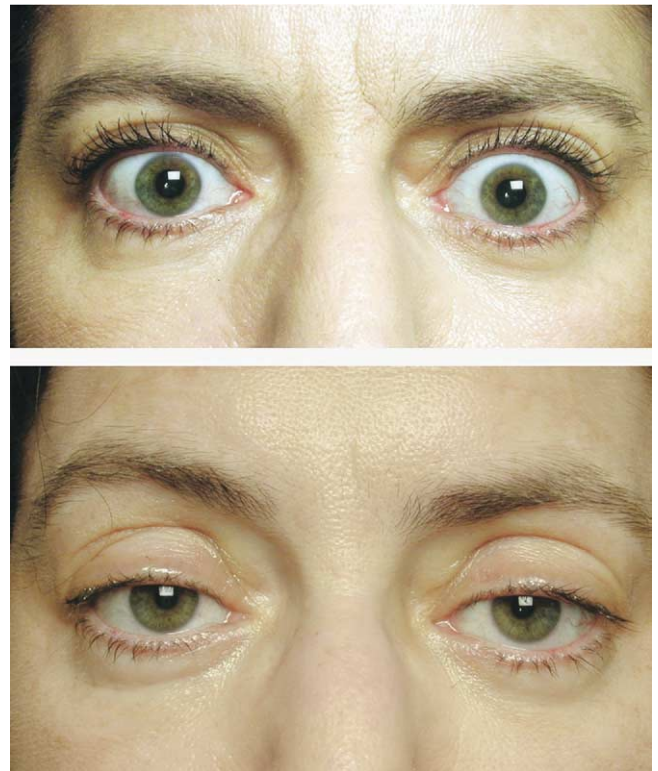or less, 8% had a difference of 1 to 2 mm, and 10% of patients showed an eyelid asymmetry of 2 mm or more ( $P = .001$ ,  $\chi^2$ ).

VA, ocular ductions, and IOP remained unchanged after surgery. Exophthalmos measurements decreased an average of 1 mm from a pre-operative value of 22.4 ( $\pm$  3.3) mm to 21.4 ( $\pm$  3.0) mm post-operatively ( $P < .05$ , paired samples t test).

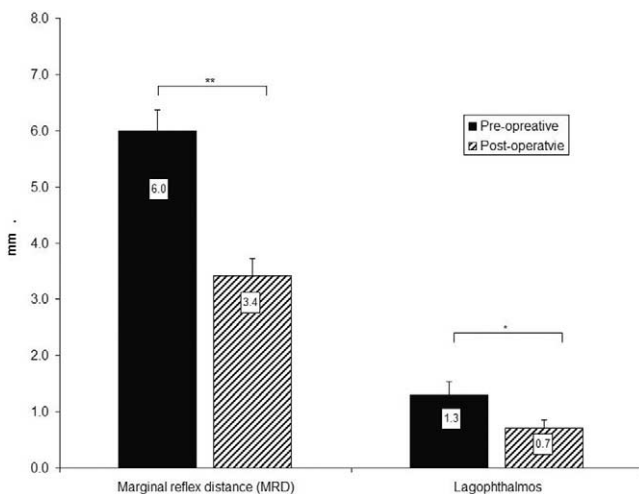
Complications included post-operative residual eyelid retraction and cosmetically unacceptable eyelid position in nine cases (8.4%). Of these, seven patients underwent additional surgery. One patient with severe debilitating recurrent TRO had a full-thickness anterior blepharotomy with levator aponeurosis spacer extension using preserved pericardium. Three cases (2.8%) showed evidence of overcorrection (Figure 5); two of those



**FIGURE 3.** A 30-year-old TRO patient with left mild upper eyelid retraction (upper image). The patient underwent Müller muscle recession on the left side; 6 months post-operatively she achieved good eyelid position and eyelid contour and excellent eyelid symmetry with less than 1-mm difference in both upper eyelids height (lower image).



**FIGURE 5.** A 41-year-old TRO patient with moderate to severe upper eyelid retraction on both sides (upper image). The patient underwent bilateral Müller muscle recession with levator disinsertion and 1 year post-operatively developed upper eyelids ptosis left more than right from overcorrection (lower image).



**FIGURE 4.** Pre-operative and post-operative values of marginal reflex distance (MRD, mm) and lagophthalmos in TRO patients undergoing Müller muscle recession with or without levator disinsertion in a 5-year period. Values are presented as mean + standard error (SE). Note marked improvement in both measurements. \*  $P < .05$ ; \*\*  $P < 0.005$ .

underwent successful ptosis correction. No patient developed wound infection or full-thickness eyelid fistula.

## DISCUSSION

POSTERIOR, TRANSCONJUNCTIVAL MÜLLER MUSCLE RESECTION with or without levator muscle aponeurosis disinsertion is effective in correcting upper eyelid retraction in TRO patients in this study.

Eyelid retraction, although a common feature of TRO, remains an enigma. Pathologic studies of Müller muscle have shown no scarring, significant inflammation, or shared antigenicity of thyroid-related antigens. Some believe that sympathetic overactivity results in contraction and degenerative changes in Müller muscle.<sup>8,18</sup> Computed tomography studies failed to show a correlation between the enlargement of the levator muscle complex or superior rectus muscle to coincide with the amount of upper eyelid retraction.<sup>19,20</sup> However, other studies have shown enlargement of the levator palpebrae muscle in TRO patients with eyelid retraction.<sup>21</sup> Investigators postulate that local adhesions of the levator muscle to fixed orbital tissues seem to be the most likely culprit.<sup>19</sup>

The purpose of correcting upper eyelid retraction in TRO patients lies in addressing symptomatology of exposure keratopathy, relief of ocular dryness, and discomfort, and esthetic restoration of pre-diseased facial appearance.

Several surgical approaches have been described to treat upper eyelid retraction,<sup>14,15,22-28</sup> all based on disinsertion of Müller muscle and levator aponeurosis from the superior tarsus. Under-correction or overcorrection, scar formation, eyelid crease asymmetry, contour abnormalities, and full-thickness eyelid perforation are all described complications.

The surgical technique used in this study was originally described by Henderson<sup>28</sup> who proposed Müller muscle myotomy and additional graded division of the levator aponeurosis in TRO patients with mild or moderate upper eyelid retraction. Although his technique proved to be rapid and effective, undercorrection was commonly noted, especially in cases presenting with lateral flare.<sup>29</sup> We have used a slightly modified technique by removing a strip of Müller muscle rather than simple myotomy and releasing the lateral horn of the levator aponeurosis from the orbital rim using the same conjunctival incision. This was carried out by blunt and sharp dissection using Stevens tenotomy scissors while manually palpating the orbital rim by way of the distal scissors tip to ensure that adequate incision and spreading were performed. Intraoperatively, frequent eyelid inversion to its normal anatomic position was done to ensure adequate correction and symmetry to the contralateral side. We feel that this technique proves to be efficient and may be performed in a graded fashion, allowing the surgeon to repair even severe cases of eyelid retraction. Undercorrection and post-operative lateral flare was not common in our patients.

Recently, a series of 32 cases of eyelid retraction treated by Koorneef-graded full-thickness anterior blepharotomy was described by Elner and associates.<sup>15</sup> Although the authors reported good surgical outcome, they claimed that other proposed surgical methods are of highly variable results with unpredictable height and contour. However, we have shown here that a slightly modified posterior-approach Müller muscle recession is predictable and results in good cosmetic and functional outcome. Our failure rate or undercorrection was relatively low (8.4%), and most of these cases improved with a second-stage surgery. Overcorrection and mild upper eyelid ptosis was noted in three cases (2.8%), proving further that a more robust effect of releasing eyelid retraction may be achieved by a more aggressive dissection of the levator aponeurosis. In Elner and associates' series,<sup>15</sup> eyelid crease recession or asymmetry occurred in 25% of cases measured; ptosis, wound dehiscence, or full-thickness perforation was noted in three patients (10%) after a mean follow-up of 8.5 months. In comparison, our current study is performed on 107 cases with a longer follow-up of 16.7 months with a lower rate of post-operative complications. Furthermore, a second surgery was successful in cases of undercorrection or residual lateral flare. Only one case required full-thickness anterior blepharotomy with the use of a spacer graft; this patient had severe debilitating recurrent episodes of thyroid orbitopathy, with marked proptosis, exposure keratopathy, and dysthyroid optic neuropathy. We feel that full-thick-

ness graded blepharotomy, with or without a spacer, is an effective technique but requires a more complex surgery, may result in eyelid crease and eyelid contour asymmetry and should be reserved for failure of posterior-approach Müller muscle recession.<sup>17,27,30</sup>

Posterior-conjunctival approach Müller muscle recession for eyelid retraction may be associated with a decrease in aqueous tear film production, leading to dry eyes, but there is a low risk for aggravating pre-existing dry eye syndrome.<sup>31</sup> We did not encounter any manifestation related to dry eyes in our patients.

In our study, upper eyelid position, lagophthalmos, exposure keratopathy and patients' discomfort markedly improved after surgery ( $P < .001$ ). MRD1 decreased an average of 2.6 ( $\pm 1.6$ ) mm from 6 ( $\pm 1.9$ ) mm pre-operatively to 3.4 ( $\pm 1.6$ ) mm post-operatively ( $P < .001$ ); lagophthalmos decreased an average of 0.6 ( $\pm 1.3$ ) mm from 1.3 ( $\pm 1.5$ ) mm pre-operatively to 0.4 ( $\pm 0.9$ ) mm post-operatively ( $P = .006$ ). Interestingly, exophthalmos measurements decreased an average of 1 mm from a pre-operative value of 22.4 mm to 21.4 mm post-operatively ( $P < .05$ , paired samples *t* test), although no orbital decompression surgery was performed and all patients were operated in the post-inflammatory phase of the disease. If this factor was not spurious, it could reflect a bias toward higher exophthalmos measurements for patients with eyelid retraction or it could reflect the natural history of the disease.

Posterior-approach Müller muscle recession avoids an external upper eyelid scar and leaves the anterior eyelid structures intact, thus facilitating, if necessary, revision by an external lid approach.

Our results suggest that posterior-approach transconjunctival Müller muscle recession along with levator muscle disinsertion results in good functional and cosmetic outcomes. It displayed high patient satisfaction regardless of the severity of pre-operative upper eyelid retraction. Recurrence rate is low and can be addressed by a second-stage surgery or a full-thickness anterior blepharotomy; overcorrection is possible and may be avoided by careful dissection and appropriate intraoperative adjustment when necessary.

---

## REFERENCES

1. Bartley GB, Fatourehchi V, Kadrmas EF, et al. Clinical features of Graves' ophthalmopathy in an incidence cohort. *Am J Ophthalmol* 1996;121:284-290.
2. Yeatts RP. Graves' ophthalmopathy. *Med Clin North Am* 1995;79:195-209.
3. Lisi S, Marino M, Pinchera A, et al. Thyroglobulin in orbital tissues from patients with thyroid-associated ophthalmopathy: predominant localization in fibroadipose tissue. *Thyroid* 2002;12:351-360.
4. Ludgate M, Crisp M, Lane C, et al. The thyrotropin receptor in thyroid eye disease. *Thyroid* 1998;8:411-413.

5. Marino M, Lisi S, Pinchera A, et al. Identification of thyroglobulin in orbital tissues from patients with thyroid-associated ophthalmopathy. *Thyroid* 2001;11:177-185.
6. Goh SY, Ho SC, Seah LL, et al. Thyroid autoantibody profiles in ophthalmic dominant and thyroid dominant Graves' disease differ and suggest ophthalmopathy is a multiantigenic disease. *Clin Endocrinol* 2004;60:600-607.
7. Chan W, Wong GW, Fan DS, et al. Ophthalmopathy in childhood Graves' disease. *Br J Ophthalmol* 2002;86:740-742.
8. Clauser L, Galie M, Sarti E, et al. Rationale of treatment in Graves ophthalmopathy. *Plast Reconstr Surg* 2001;108:1880-1894.
9. Gay AJ, Wolkstein MA. Topical guanethidine therapy for endocrine lid retraction. *Arch Ophthalmol* 1966;76:364-367.
10. Ebner R. Botulinum toxin type A in upper lid retraction of Graves' ophthalmopathy. *J Clin Neuroophthalmol* 1993;13:258-261.
11. Uddin JM, Davies PD. Treatment of upper eyelid retraction associated with thyroid eye disease with subconjunctival botulinum toxin injection. *Ophthalmology* 2002;109:1183-1187.
12. Putterman A, Fett DR. Müller's muscle in the treatment of upper eyelid retraction: a 12-year study. *Ophthalmic Surg* 1986;17:361-367.
13. Baylis HI, Cies WA, Kamin DF. Correction of upper eyelid retraction. *Am J Ophthalmol* 1976;82:790-794.
14. Grove AS Jr. Eyelid retraction treated by levator marginal myotomy. *Ophthalmology* 1980;87:1013-1018.
15. Elner VM, Hassan AS, Frueh BR. Graded full-thickness anterior blepharotomy for upper eyelid retraction. *Arch Ophthalmol* 2004;122:55-60.
16. Grove AS Jr. Upper eyelid retraction and Graves' disease. *Ophthalmology* 1981;88:499-506.
17. Hedin A. Eyelid surgery in dysthyroid ophthalmopathy. *Eye* 1988;2:201-206.
18. Kagoshima T, Hori S, Inoue Y. Qualitative and quantitative analyses of Müller's muscle in dysthyroid ophthalmopathy. *Jpn J Ophthalmol* 1987;31:646-654.
19. Feldon SE, Levin L. Graves' ophthalmopathy: V. Aetiology of upper eyelid retraction in Graves' ophthalmopathy. *Br J Ophthalmol* 1990;74:484-485.
20. Rootman J, Patel S, Berry K, et al. Pathological and clinical study of Muller's muscle in Graves' ophthalmopathy. *Can J Ophthalmol* 1987;22:32-36.
21. Inoue Y, Higashide T, Yoshikawa K, et al. Sagittal magnetic resonance imaging of dysthyroid ophthalmopathy. *Eur J Ophthalmol* 1993;3:31-36.
22. Mourits M, Sasim IV. A single technique to correct various degrees of upper lid retraction in patients with Graves' orbitopathy. *Br J Ophthalmol* 1999;83:81-84.
23. Putterman AM, Urist M. Surgical treatment of upper eyelid retraction. *Arch Ophthalmol* 1972;87:401-405.
24. Putterman AM. Surgical treatment of thyroid-related upper eyelid retraction. Graded Muller's muscle excision and levator recession. *Ophthalmology* 1981;88:507-512.
25. Harvey JT, Anderson RL. The aponeurotic approach to eyelid retraction. *Ophthalmology* 1981;88:513-524.
26. Ceisler EJ, Bilyk JR, Rubin PA, et al. Results of Mullerectomy and levator aponeurosis transposition for the correction of upper eyelid retraction in Graves disease. *Ophthalmology* 1995;102:483-492.
27. Fenton S, Kemp EG. A review of the outcome of upper lid lowering for eyelid retraction and complications of spacers at a single unit over five years. *Orbit* 2002;21:289-294.
28. Henderson JW. A surgical procedure for retraction of eyelids in endocrine exophthalmos (a moving picture). *Trans Am Ophthalmol Soc* 1965;63:70-74.
29. Hurwitz JJ, Rodgers KJ. Prevention and management of postoperative lateral upper-lid retraction in Graves' disease. *Can J Ophthalmol* 1983;18:329-332.
30. Mourits M, Koornneef L. Lid lengthening by sclera interposition for eyelid retraction in Graves' ophthalmopathy. *Br J Ophthalmol* 1991;75:344-347.
31. George JL, Tercero ME, Angioi-Duprez K, et al. Risk of dry eye after Mullerectomy via the posterior conjunctival approach for thyroid-related upper eyelid retraction. *Orbit* 2002;21:19-25.



### **Biosketch**

Guy J. Ben Simon, MD, has participated in blind tours (cataract surgeries) organized by the Bureau for Prevention of Blindness, South Africa, and in a delegation organized by the Israeli Ministry of Foreign Affairs to Micronesia to perform cataract surgeries and laser treatments for diabetes. Dr. Ben Simon's primary research interests include orbital surgery and orbital tumors; traumatic optic neuropathy (optic nerve crush and pressure injury in rats, Weizmann Institute of Science & Neurotrauma laboratory, UCLA), and international ophthalmology.