

Clinical Manifestations and Treatment Outcome of Optic Neuropathy in Thyroid-Related Orbitopathy

Guy J. Ben Simon, MD; Hasan Syed, MD; Raymond Douglas, MD, PhD; Robert Schwartz, MD; Robert A. Goldberg, MD; John D. McCann, MD, PhD

■ **BACKGROUND AND OBJECTIVE:** To investigate the incidence and outcome of optic neuropathy associated with thyroid-related orbitopathy.

■ **PATIENTS AND METHODS:** All patients diagnosed as having optic neuropathy associated with thyroid-related orbitopathy who underwent treatment for optic neuropathy between January 1, 1999, and March 1, 2003, were reviewed. Demographic and clinical data were extracted from the oculoplastic registry (electronic medical record).

■ **RESULTS:** Optic neuropathy occurred in 20 of 595 patients with thyroid-related orbitopathy (3.4%). All patients received systemic steroids, 7 patients received orbital steroid injections, and 2 patients were treated with orbital radiotherapy. Orbital decompression was performed in all 26 orbits. Visual acuity im-

proved from a mean of 20/150 to 20/30 ($P < .001$). Color vision improved from a mean of 5.2/14 to 11/14 ($P = .001$). The afferent pupillary defect disappeared shortly after treatment for all but 1 case, and improved in all cases. Exophthalmos decreased from 26.4 ± 2.5 to 21.5 ± 2.1 mm ($P < .001$; 95% confidence interval, 3.8 to 5.7).

■ **CONCLUSIONS:** Optic neuropathy manifests rarely in patients with thyroid-related orbitopathy. Monitoring visual acuity or afferent pupillary response may be a reliable way of assessing and monitoring optic neuropathy. In this study, patients had improved visual acuity and optic nerve function after a combination of medical and surgical treatment.

[*Ophthalmic Surg Lasers Imaging* 2006;37:284-290.]

INTRODUCTION

Optic neuropathy in patients with thyroid-related orbitopathy is considered a serious diagnosis that

requires prompt treatment to prevent permanent visual loss.¹ It is believed that compression of the optic nerve at the orbital apex by extraocular muscle enlargement,²⁻⁴ inflammation,⁵ and vasculopathy⁶ are the main causes of neuropathy. In rare cases, increased orbital fat associated with axial proptosis can cause optic nerve dysfunction without crowding in the orbital apex by stretching the nerve.⁷

There are no clear guidelines for the sequence of treatment of optic neuropathy, but many therapeutic

From the Jules Stein Eye Institute and the Department of Ophthalmology, David Geffen School of Medicine at UCLA, Los Angeles, California.

Accepted for publication March 10, 2006.

Address reprint requests to Guy J. Ben Simon, MD, Goldschleger Eye Institute, Sheba Medical Center, Tel Hashomer, Israel 52621.

options are available. Treatments that have proved to be beneficial in optic neuropathy are systemic steroids,⁸ intravenous pulse methylprednisolone,^{9,10} chemotherapy,⁸ radiotherapy,^{8,11,12} orbital decompression by bone removal,¹³⁻¹⁶ and orbital decompression by fat removal.¹⁷ Bony decompression of the orbit can be curative, but previous reports include cases with persistent signs of optic nerve dysfunction that require re-treatment with steroids, radiotherapy, or even repeated surgery.¹³

The purpose of this study was to evaluate the treatment results of cases with optic neuropathy, and to provide long-term follow-up. Treatment consisted of systemic steroids, orbital injection of steroids, orbital decompression, and radiotherapy.

PATIENTS AND METHODS

This study was a retrospective, noncomparative, interventional cases series. The oculoplastic registry was reviewed to identify all patients treated for optic neuropathy associated with thyroid-related orbitopathy at the Jules Stein Eye Institute between January 1, 1999, and March 1, 2003. The study complied with the policies of the local institutional review board. Data regarding visual acuity, relative afferent pupillary defect, color vision, red desaturation, brightness, intraocular pressure (IOP), exophthalmometry, treatment modality, outcome, and complications were recorded and analyzed.

Treatment for optic neuropathy at our center consisted of at least one of the following four modalities: systemic steroids (1 to 2 mg/kg), orbital injection of triamcinolone acetonide (40 mg/1 mL), orbital radiation, and orbital decompression (bony removal of medial and, in some cases, lateral orbital wall). All surgeries were performed by two of the authors (RAG and JDM). Most patients who underwent orbital decompression received systemic steroids before surgery. In some patients, an attempt was made to reduce the need for systemic steroids by giving orbital injections of triamcinolone acetonide. Six patients had bilateral optic neuropathy, as evidenced by decreased visual acuity, or color vision. The urgency to perform orbital decompression was based on the visual acuity trajectory and the presence of orbital inflammation.

Statistical analysis was performed using the paired samples *t* test to evaluate preoperative and postoperative data such as visual acuity, IOP, and exophthalmometry

measurements. Pearson bivariate correlation was used to examine influence of age, visual acuity, IOP, color vision, and extent of exophthalmos and treatment outcome.

RESULTS

Of 595 patients with thyroid-related orbitopathy, 26 eyes of 20 patients (3.4%; 4 men, 16 women) were diagnosed as having optic neuropathy. Data regarding patient demographics are summarized in Table 1.

Most of the patients (85%; 17 of 20) were receiving thyroid hormone replacement therapy. Optic neuropathy affected the right eye in 42% of cases and the left eye in 58%. Diagnosis of optic neuropathy was made on the basis of at least one of the following: decreased best-corrected visual acuity (96.2%), decreased color vision (Ishihara) or red desaturation (76%), and decreased brightness and relative afferent pupillary defect (69%). Afferent pupillary defect was graded clinically according to severity on a scale of 1 to 4. Mean clinical scale of afferent pupillary defect was 1.7 ± 1 (0 to 4).

Treatment for optic neuropathy consisted of at least one of four modalities that are summarized in Table 2. All 20 patients had received oral prednisone at some time during their treatment course. All 26 orbits underwent decompression (20 cases = medial wall, 6 cases = combined medial and lateral walls), 7 patients were treated with orbital injection of triamcinolone acetonide (40 mg), and 2 patients were treated with radiotherapy. Eight patients (32%) received systemic steroid treatment after orbital decompression for either postoperative orbital inflammation or persistent signs of optic nerve dysfunction.

Average visual acuity improved from a mean of 20/150 to 20/30 after treatment ($P < .001$; 95% confidence interval, 0.45 to 0.9), delta logarithm of the minimum angle of resolution (visual acuity) was 0.68 ± 0.55 (range, 0 to 1.81) (Figs. 1 and 2). Older patients demonstrated less improvement in visual acuity after treatment ($r = -0.54$; $P = .006$, Pearson correlation). No patient had a decrease in visual acuity as a result of treatment. Mean Ishihara color plate values increased from $5.2/14 \pm 4$ (range, 0 to 10) at the time of diagnosis to $11/14 \pm 3$ (range, 6 to 14) post-treatment ($P = .001$; 95% confidence interval, -8 to -3).

Orbital decompression was performed at different intervals after diagnosis of optic neuropathy. Medi-

TABLE 1
Pretreatment and Posttreatment Data of the Study Group

Characteristic	At Diagnosis* Mean ± SD (Range)	Post-treatment† Mean ± SD (Range)	P
Age (y)	50.3 ± 15.7 (22–76)		
Duration of Graves' ophthalmopathy (y)	3.9 ± 3.8 (0.25–15)		
logMAR (visual acuity)	0.88 ± 0.59 (0.1–1.9)	0.2 ± 0.23 (0–1.0)	< .001
Visual acuity	20/150 (20/25–HM)	20/30 (20/25–20/200)	< .001
Color vision (Ishihara) – n/14	5.2 ± 4 (0–10)	11 ± 3 (6–14)	.001
IOP primary gaze (mm Hg)	19.6 ± 6.4 (8–42)	17.5 ± 4.3 (11–25)	.035
IOP up gaze (mm Hg)	30.8 ± 8.5 (21–48)	20.5 ± 5.3 (12–33)	< .001
IOP difference (up–primary) (mm Hg)‡	11.3 ± 6.5 (2–26)	2.6 ± 2.8 (0–8)	< .001
Exophthalmometry (mm)	26.4 ± 2.5 (21–30)	21.5 ± 2.1 (16–26)	< .001
Follow-up time (mo)		17 ± 9 (6–37)	

SD = standard deviation; logMAR = logarithm of the minimum angle of resolution; HM = hand motions; IOP = intraocular pressure.

*Measurements taken at the time of diagnosis of optic neuropathy.

†Measurements taken at the last follow-up after surgical (orbital decompression) and medical (systemic/orbital steroids) treatment.

‡Difference of IOP in up gaze to IOP in primary gaze, as an indication for the extent of mechanical restriction preoperatively and functional decompression after surgery.

TABLE 2
Treatment Modalities in the Study Group

Treatment Sequence*	Systemic Prednisone†	Retrobulbar Triamcinolone Acetonide	Radiation	Orbital Decompression‡
1st	17			12
2nd	5	7	1	6
3rd	4		1	7
4th				1
Total	26	7	2	26

*Patients could have been treated with at least one of four treatment modalities. Treatment sequence denotes which treatment modality was applied first.

†Oral prednisone (1 to 2 mg/kg).

‡Bony decompression (removal of medial and, in some cases, inferior orbital wall).

cal treatment was employed and surgery was delayed as long as visual acuity remained stable (Fig. 3). Results of ophthalmoscopy examination were normal for most cases and optic nerve changes were noted in only 4 cases (15.4%); these included mild hyperemia with congestion, indistinct margins, optic disc edema, and regional pallor.

Afferent pupillary defect disappeared after treatment in all but 1 case, who initially presented with a dense afferent pupillary defect that decreased to trace defect after treatment. There was a reduction in mean

primary gaze IOP measurements of 4.3 ± 7.3 mm Hg from a mean pretreatment value of 19.6 ± 6.4 to 17.5 ± 4.3 ($P = .035$). Mean IOP in up gaze also decreased by 13.6 ± 7.3 mm Hg (44%), from 30.8 ± 8.5 mm Hg pretreatment to 20.5 ± 5.3 mm Hg post-treatment ($P < .001$; 95% confidence interval, 9.4 to 17.8). There was a correlation in terms of the degree of surgical exophthalmos correction and reduction in up gaze IOP ($r = 0.74$; $P = .014$).

After orbital decompression, exophthalmometry measurements decreased 4.8 ± 2.1 mm (range, 1 to 8

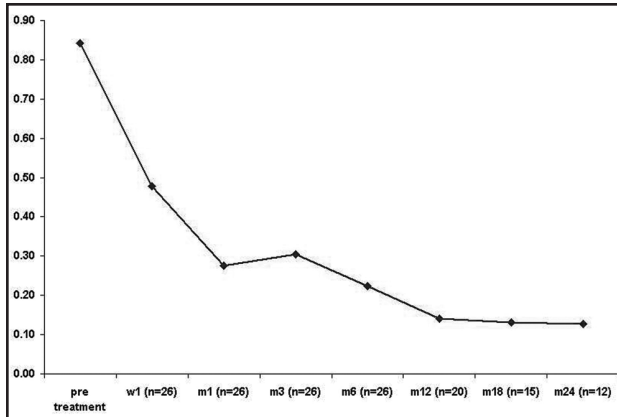


Figure 1. Change of the logarithm of the minimum angle of resolution (logMAR) of visual acuity from time of diagnosis (pre-treatment) to 2 years after treatment (orbital decompression and steroids).

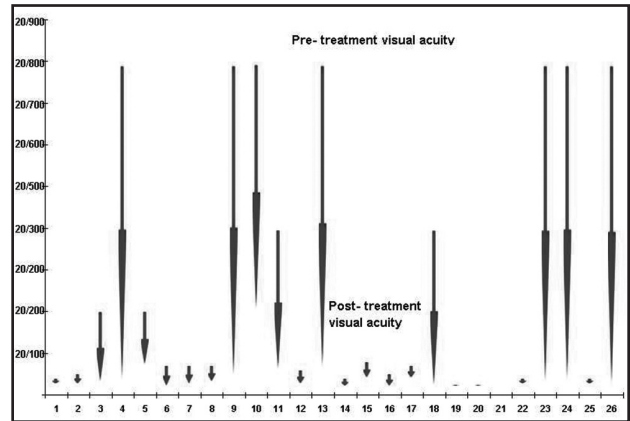


Figure 2. Pretreatment and post-treatment change in visual acuity in patients with optic neuropathy (X axis represents all 26 cases); top of arrow indicates initial visual acuity, arrowhead points to final visual acuity (post-treatment).

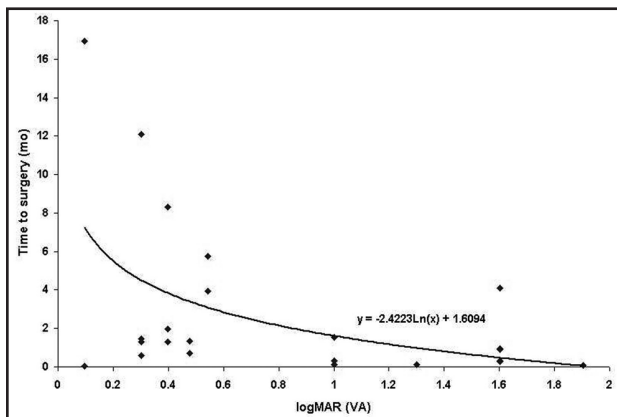


Figure 3. Time (months) from diagnosis of optic neuropathy to orbital decompression as a function of the logarithm of the minimum angle of resolution (logMAR) of presenting visual acuity (VA).

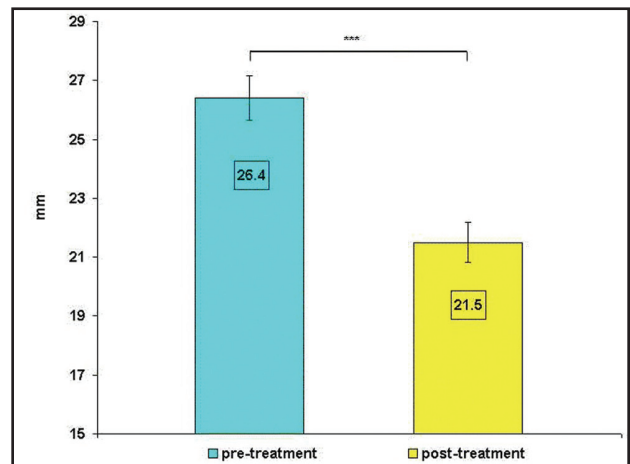


Figure 4. Exophthalmometry measurements (mean \pm standard error) before and after orbital decompression for optic neuropathy. *** $P < .001$.

mm), from 26.4 ± 2.5 mm (range, 21 to 30 mm) to 21.5 ± 2.1 mm (range, 16 to 26 mm) ($P < .001$; 95% confidence interval, 3.8 to 5.7) (Fig. 4). No complications were associated with orbital decompression or orbital steroid injection. Systemic steroids were used for an average of 3 ± 2 weeks (range, 3 days to 2.5 months).

DISCUSSION

Optic neuropathy is a rare manifestation of thyroid-related orbitopathy, and only 3.4% of all patients in our study exhibited signs of optic nerve dysfunction. This is a lower incidence than the 8.6% originally reported by Neigel et al.¹ Bilateral decrease in visual acuity was seen in only 6 patients (30%).

Decreased visual acuity was the most common presentation of optic neuropathy in our patients. Mean pretreatment visual acuity was 20/150, worse than previously reported by Neigel et al.'s group,¹ where 52.6% of the patients had a visual acuity of 20/40 or better at the time of diagnosis. This disparity may be the result of patients in our group presenting with more advanced optic neuropathy. We did not examine contrast sensitivity, visual evoked potentials, or visual fields, which would probably demonstrate optic nerve dysfunction before the visual acuity deteriorates.^{1,18-21}

Afferent pupillary defect was noticed in 69% of the cases, a higher rate than found by Neigel et al.,¹ who reported 34.8% in their optic neuropathy group. Again, this may imply that our patients were diagnosed

at a more severe stage. Color vision disturbances were found in 76% of our patients. The fact that results of color vision examination by Ishihara color plates did not return to normal may imply that some degree of optic nerve dysfunction remains after orbital decompression and steroid treatment, even if visual acuity returns to normal and afferent pupillary defect disappears. It may be that color vision is the more sensitive method of evaluating minor degrees of optic neuropathy in the clinic, possibly due to the fact that it is not a relative examination (as is pupillary response). It is also known that in optic neuropathy of different etiologies, color vision may be disturbed before visual acuity deteriorates, and may persist even after treatment.²²⁻²⁶

An important mechanism for optic neuropathy is optic nerve compression at the orbital apex caused by enlargement of the recti muscles.¹⁻⁴ Patients with optic neuropathy commonly demonstrate restriction of the inferior rectus muscle¹ and an associated increase in IOP in up gaze. In our patients, the mean increase in IOP between primary gaze and up gaze was reduced by 11.3 ± 6.5 mm Hg after treatment. It seems unlikely that orbital decompression reduced the fibrosis of the inferior rectus muscle. We speculate that retrodisplacement of the globe within the orbit reduces the tension on the inferior rectus muscle so that the globe can supraduct with less restriction from the inferior rectus muscle.

Our patients showed an increased IOP in primary gaze, which can imply more congestion, and increased intraorbital pressure as a sign for severity of the disease.^{27,28} Otto et al. noted that retrobulbar pressure is elevated in patients with optic neuropathy compared with patients who have Graves' ophthalmopathy without optic neuropathy, and orbital decompression surgery results in a marked decrease in retrobulbar pressure. This may be one of the mechanisms of improved optic nerve perfusion after decompression surgery.²⁸

Age is considered a risk factor in optic neuropathy, and Neigel et al.¹ found patients with optic neuropathy to be older than patients who had thyroid-related orbitopathy without optic neuropathy (57.5 vs 49.2 years). Our patients were relatively young with a mean age of 50.3 years, but older patients demonstrated less improvement in visual acuity after treatment ($r = -0.54$; $P = .006$). It may be that other factors may influence optic nerve dysfunction in older age, such as the presence of microcirculatory abnormalities due to atherosclero-

sis, hypertension, or diabetes, which are risk factors for the development of optic neuropathy in patients with thyroid-related orbitopathy.⁶

All of our patients demonstrated marked improvement in visual acuity and optic nerve functions after treatment with orbital decompression and systemic or orbital steroid injections. This supports the theory that optic nerve compression in the orbital apex and decreased optic nerve perfusion (caused by tight orbit) are the main mechanisms of optic nerve dysfunction in thyroid-related orbitopathy. Thirty-two percent of our patients initially received steroids after surgery to treat postoperative inflammation and to allow for tapering of their preoperative steroids.

Only one patient required a second orbital decompression procedure. The first orbital decompression procedure improved the visual acuity from 20/200 to 20/60, but visual acuity decreased to 20/100 in the year after surgery. It is questionable whether this was due to optic neuropathy or severe diabetic retinopathy. The second decompression did not result in visual acuity improvement.

Our results are not in accord with what has been previously reported by Hutchison and Kyle,¹³ who found subsequent deterioration in vision in 36% of patients who underwent orbital decompression for optic neuropathy. These patients later responded to additional treatment with systemic steroids, orbital radiotherapy, or further orbital surgery. In two of Hutchison and Kyle's patients (6%), vision continued to deteriorate despite further treatment. All cases that were treated with steroids preoperatively showed improvement in vision. Other studies have shown that combined immunosuppression (azathioprine or low-dose prednisolone) with primary orbital radiotherapy in the management of active thyroid eye disease led to fewer side effects than high-dose steroids. There was even a fourfold reduction in the requirement for orbital decompression and strabismus surgery.⁸ We cannot conclude from our study any specific role of steroids or radiotherapy on optic neuropathy because most of our patients were treated with steroids and orbital decompression and only two were treated with radiation alone.

We found that steroids combined with orbital decompression are an effective treatment for optic neuropathy in thyroid-related orbitopathy. We think that a trial of steroids is indicated as an initial treatment

in most patients with optic neuropathy. Most patients with optic neuropathy are in the active inflammatory phase of the disease and it is our experience that steroids decrease orbital congestion, facilitating a safer decompression surgery. We would forgo the initial trial of steroids and proceed directly to surgery in the following situations: presenting visual acuity of less than 20/200, exposure keratopathy with corneal ulceration, and contraindications to systemic steroids.

If steroid treatment succeeds in improving vision, a close and careful evaluation of the patient should be made because steroid tapering may be associated with rebound optic neuropathy. Prolonged treatment with systemic steroids has a significant associated morbidity. We try to minimize this morbidity by giving orbital steroid injections while tapering systemic steroids. In cases that require systemic steroids to maintain visual acuity, we proceed to surgery because in our cases surgery was associated with little morbidity. The goal of management in patients without visual impairment is to delay decompression surgery until the disease is stable.

Medial wall decompression (which was performed in 20 of 26 eyes) suffices in achieving clinical improvement. Other types of orbital decompression may be equivalent in effectiveness in treating optic neuropathy. We tried to perform the minimal amount of surgery to relieve the optic neuropathy. The benefit of more extensive orbital surgery might be better reduction of proptosis, but it may also be associated with a higher rate of complications.

Limitations of the study stem from its retrospective design. One cannot evaluate the specific role of each of the treatment modalities and their outcome. The natural history of optic neuropathy in thyroid-related orbitopathy is not clear, but, given the vulnerable nature of neuronal tissue to ischemia or mechanical injury intervention, must be contemplated whenever signs of severe nerve dysfunction appear. Further comparative, prospective studies are needed to investigate the specific management of optic neuropathy in thyroid-related orbitopathy and to propose clear guidelines for treatment based on clinical and laboratory findings.

REFERENCES

1. Neigel JM, Rootman J, Belkin RI, et al. Dysthyroid optic neuropathy: the crowded orbital apex syndrome. *Ophthalmology*. 1988;95:1515-1521.
2. Kennerdell JS, Rosenbaum AE, El-Hoshy MH. Apical optic nerve compression of dysthyroid optic neuropathy on computed tomography. *Arch Ophthalmol*. 1981;99:807-809.
3. Gass A, Barker GJ, MacManus D, et al. High resolution magnetic resonance imaging of the anterior visual pathway in patients with optic neuropathies using fast spin echo and phased array local coils. *J Neurol Neurosurg Psychiatry*. 1995;58:562-569.
4. Giaconi JA, Kazim M, Rho T, Pfaff C. CT scan evidence of dysthyroid optic neuropathy. *Ophthalm Plast Reconstr Surg*. 2002;18:177-182.
5. Trobe JD, Glaser JS, Laflamme P. Dysthyroid optic neuropathy: clinical profile and rationale for management. *Arch Ophthalmol*. 1978;96:1199-1209.
6. Kalmann R, Mourits MP. Diabetes mellitus: a risk factor in patients with Graves' orbitopathy. *Br J Ophthalmol*. 1999;83:463-465.
7. Anderson RL, Tweeten JP, Patrinely JR, Garland PE, Thiese SM. Dysthyroid optic neuropathy without extraocular muscle involvement. *Ophthalmic Surg*. 1989;20:568-574.
8. Claridge KG, Ghabrial R, Davis G, et al. Combined radiotherapy and medical immunosuppression in the management of thyroid eye disease. *Eye*. 1997;11:717-722.
9. Guy JR, Fagien S, Donovan JP, Rubin ML. Methylprednisolone pulse therapy in severe dysthyroid optic neuropathy. *Ophthalmology*. 1989;96:1048-1052.
10. Ph Mourits M, Kalmann R, Sasim IV. Methylprednisolone pulse therapy for patients with dysthyroid optic neuropathy. *Orbit*. 2001;20:275-280.
11. Kinyoun JL, Kalina RE, Brower SA, Mills RP, Johnson RH. Radiation retinopathy after orbital irradiation for Graves' ophthalmopathy. *Arch Ophthalmol*. 1984;102:1473-1476.
12. Rush S, Winterkorn JM, Zak R. Objective evaluation of improvement in optic neuropathy following radiation therapy for thyroid eye disease. *Int J Radiat Oncol Biol Phys*. 2000;47:191-194.
13. Hutchison BM, Kyle PM. Long-term visual outcome following orbital decompression for dysthyroid eye disease. *Eye*. 1995;9:578-581.
14. Liao SL, Kao SC, Hou PK, Chen MS. Results of orbital decompression in Taiwan. *Orbit*. 2001;20:267-274.
15. Asaria RH, Koay B, Elston JS, Bates GE. Endoscopic orbital decompression for thyroid eye disease. *Eye*.

- 1998;12:990-995.
16. Gormley PD, Bowyer J, Jones NS, Downes RN. The sphenoidal sinus in optic nerve decompression. *Eye*. 1997;11:723-726.
 17. Kazim M, Trokel SL, Acaroglu G, Elliott A. Reversal of dysthyroid optic neuropathy following orbital fat decompression. *Br J Ophthalmol*. 2000;84:600-605.
 18. Ambrosio G, Ferrara G, Vitale R, De Marco R. Visual evoked potentials in patients with Graves' ophthalmopathy complicated by ocular hypertension and suspect glaucoma or dysthyroid optic neuropathy. *Doc Ophthalmol*. 2003;106:99-104.
 19. De Marco R, Ambrosio G, Ferrara G. Measuring contrast sensitivity in patients with Graves' ophthalmopathy complicated by ocular hypertension and suspect glaucoma or dysthyroid optic neuropathy. *Doc Ophthalmol*. 2000;101:165-77.
 20. Suttorp-Schulten MS, Tijssen R, Mourits MP, Apkarian P. Contrast sensitivity function in Graves' ophthalmopathy and dysthyroid optic neuropathy. *Br J Ophthalmol*. 1993;77:709-712.
 21. Tsaloumas MD, Good PA, Burdon MA, Misson GP. Flash and pattern visual evoked potentials in the diagnosis and monitoring of dysthyroid optic neuropathy. *Eye*. 1994;8:638-645.
 22. The Optic Neuritis Study Group. Visual function 5 years after optic neuritis: experience of the Optic Neuritis Treatment Trial. *Arch Ophthalmol*. 1997;115:1545-1552.
 23. Frederiksen JL, Sorensen TL, Sellebjerg FT. Residual symptoms and signs after untreated acute optic neuritis: a one-year follow-up. *Acta Ophthalmol Scand*. 1997;75:544-547.
 24. Schneck ME, Haegerstrom-Portnoy G. Color vision defect type and spatial vision in the optic neuritis treatment trial. *Invest Ophthalmol Vis Sci*. 1997;38:2278-2289.
 25. Nichols BE, Thompson HS, Stone EM. Evaluation of a significantly shorter version of the Farnsworth-Munsell 100-hue test in patients with three different optic neuropathies. *Neuro-ophthalmology*. 1997;17:1-6.
 26. Trobe JD, Beck RW, Moke PS, Cleary PA. Contrast sensitivity and other vision tests in the Optic Neuritis Treatment Trial. *Am J Ophthalmol*. 1996;121:547-553.
 27. Kalmann R, Mourits MP. Prevalence and management of elevated intraocular pressure in patients with Graves' orbitopathy. *Br J Ophthalmol*. 1998;82:754-757.
 28. Otto AJ, Koornneef L, Mourits MP, Deen-van Leeuwen L. Retrobulbar pressures measured during surgical decompression of the orbit. *Br J Ophthalmol*. 1996;80:1042-1045.

Reproduced with permission of the copyright owner. Further reproduction prohibited without permission.